

AWARENESS OF HERPANGINA AND ITS MANAGEMENT AMONG DENTAL STUDENTS

Reshma Thirunavakarasu¹, Dhanraj Ganapathy², Subhashree Rohinikumar³

Abstract

Herpangina or otherwise known as hand-foot and mouth disease is caused by enteroviral infection and are two common related clinical syndromes. This diseases are mostly seen in paediatric population . It is occasionally seen among adult patients. Herpangina is caused by one particular strain of coxsackie virus A and Enterovirus -A71 .The aim of the study was to determine if dental students are aware of the various managements done for herpangina.

A survey with 9 close ended questions and 3 multiple choice questions were formed and distributed to 100 dental students respectively. Their responses will determine the level of awareness of students regarding the management of herpangina. The questions elicited awareness on the various aspects of Herpangina disease among dental students..These responses to these questions were tabulated and analysed. 55% of the respondents said Herpangina affected people aged between 3-10yrs . 75% respondents said Herpangina is caused by Group A coxsackieviruses followed by 20% said Streptococcus and 5% said Staphylococcus are responsible. 83% of respondent prescribed antivirals followed by analgesics 15% and 2% used antibiotics to treat Herpangina.The awareness about the management strategies of Herpangina among dental students was moderate.Awareness of dental students can always be enhanced by promoting more educational programmes regarding various diseases such as herpangina. It is important as they will play an important role in delivering better health care in the future.

Keywords: Awareness, Herpangina, dental students.

Introduction

Fixed prosthodontic treatment deals with the replacement of teeth by artificial substitutes that are not readily removable from the mouth. Its focus is to restore function, esthetics and comfort[1]The fixed partial denture (FPD) is one of the most commonly preferred treatment options for a single missing tooth.[2] FPDs were considered to be the best treatment choice for replacing a single missing tooth[3] Fixed prosthodontics treatment can range from the restoration of a single tooth to rehabilitation [4]

¹ Undergraduate student, Department of Prosthodontics, Saveetha Dental College and Hospitals, Saveetha Institute of Medical and Technical Sciences, Chennai, India .

² Professor & Head of Department, Department of Prosthodontics, Saveetha Dental College and Hospitals, Saveetha Institute of Medical and Technical Sciences, Chennai, India, Email: dhanrajmganapathy@yahoo.co.in

³ Senior Lecturer, Department of Prosthodontics, Saveetha Dental College and Hospitals, Saveetha Institute of Medical and Technical Sciences, Chennai, India

Herpangina or otherwise known as hand-foot and mouth disease (HFMD) is caused by enteroviral infection and are two common related clinical syndromes. These diseases are mostly seen in paediatric population (7 to 10 years). It is occasionally seen among adult patients. (Yu et al., 2020) Herpangina is caused by one particular strain of coxsackie virus A (CV-A) and Enterovirus -A71 (EV-A71). Herpangina is an acute upper respiratory tract infection. It was found that patients/ individuals with latent infections are the ones who can easily spread the infection. Typical spread of this disease is via fecal-oral route. Transmission can be from the ingestion of infected saliva, respiratory droplets or direct contact with fluid from vesicles. Incubation period of 3-5 days. (Kılınc & Akbaş, 2018; Palani et al., 2018.)

There are various clinical manifestations to this disease. Herpangina is an acute disease which is characterised by a sudden onset of fever and sore throat followed by fever which may last up to 2-4 days. Cough, rhinorrhoea, vomiting, diarrhoea and sometimes headache, abdominal pain or myalgia and dysphagia in severe sore throat cases can be seen (Pongsumpun & Wongvanich, 2018) Skin eruptions is manifested as papules or vesicles or petechiae on the hand and/or feet or as aphthae on the tongue and oral mucosa. (Woodland, 2019) There are various oral manifestations as well to this disease such as vesicles, ulceration and diffuse erythema on the soft palate, fauces and tonsillar area (Palmer et al., 1963; Woodland, 2019) Various differential diagnosis can be given to this disease such as herpetic gingivostomatitis, ulcerative stomatitis, measles and varicella. (Zhang et al., 2015)

The only treatment available for this disease is primary supportive treatments. There is no prophylaxis for herpangina or HFMD (Lalya & Mansouri, 2016) Since herpangina and HFMD disease are self-limiting or short duration and does not require treatment. Symptomatic treatment is indicated in very severe cases of herpangina in which non-aspirin antipyretics and topical anaesthetics can be used. (Chen et al., 2020) Lidocaine or topical therapies are not recommended due to the risks for toxicity associated with these medications. The use of intravenous immunoglobulin (IVIG) in Asia to treat patients with herpangina has shown major outbreaks however it has no prospective data collected about the use of this drug. (Duan et al., 2008) The aim of this study is to determine if dental students are aware of the various managements done for herpangina.

Materials and Methods

A survey with 9 close ended questions and 3 multiple choice questions were formed and distributed to dental students (3rd Yrs, 4th Yrs and Interns) as shown in Table 1 and Table 2 respectively. These responses to these questions were tabulated then analysed and studied. Their responses will determine the level of awareness of students regarding the management of herpangina

Table 1 : Closed ended questions

1. Are you aware of the disease known as herpangina?	Yes	No
2. Are you aware of its other name?	Yes	No
3. Is herpangina contagious?	Yes	No
4. Is herpangina a viral infection?	Yes	No
5. Is there an antiviral therapy for herpangina?	Yes	No
6. Can herpangina be prevented?	Yes	No
7. Does herpangina cause any signs in the oral cavity?	Yes	No
8. Will mouthwashes help control mouth pain in herpangina patient ?	Yes	No
9. Will a change of diet aid in treatment ?	Yes	No

Table 2: Multiple choice questions

Question:	A	B	C	D
10. Which age group of people are mostly affected?	3-10 yrs	11-19yrs	20-30yrs	31-40yrs
11. Which organism causes herpangina?	Group A coxsackieviruses	Staphylococcus	Streptococcus	
12. What medication are advised?	Antibiotics	antivirals	No medications. Only analgesics	

Results

A total of 100 students have participated in this survey. The results were obtained and tabulated. Table and charts are done to depict clearly the level of knowledge the students have towards the disease as well as its managements .[Table 3,Charts 1-3]Chart 1 shows that 55% of the respondents said Herpangina affected people

aged between 3-10yrs . Chart 2 shows 75% respondents said Herpangina is caused by Group A coxsackieviruses followed by 20% said Streptococcus and 5% said Staphylococcus are responsible. Chart 3 shows majority of respondents , 83% of respondent prescribed antivirals followed by analgesics 15% and 2% used antibiotics to treat Herpangina.

Table 3 :Responses

Questions	Yes	No
Are you aware of the disease known as herpangina?	86	14
Are you aware of its other name?	43	57
Is herpangina contagious?	89	11
Is herpangina a viral infection?	89	11
Is there an antiviral therapy for herpangina?	47	53
Can herpangina be prevented?	93	7
Does herpangina cause any signs in the oral cavity?	97	3
Will mouthwashes help control mouth pain in herpangina patient ?	79	21
Will a change of diet aid in treatment ?	69	31

Chart 1 : Affected Age Group

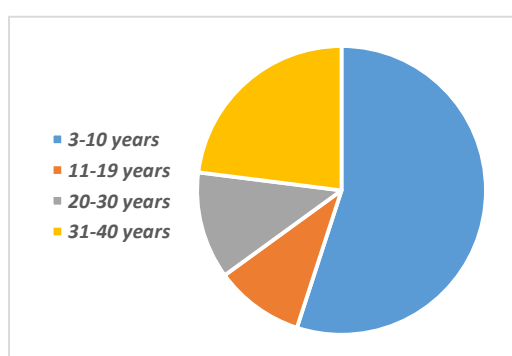


Chart 2: Causative Organism

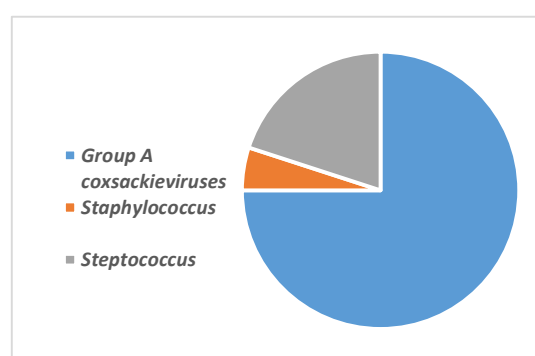
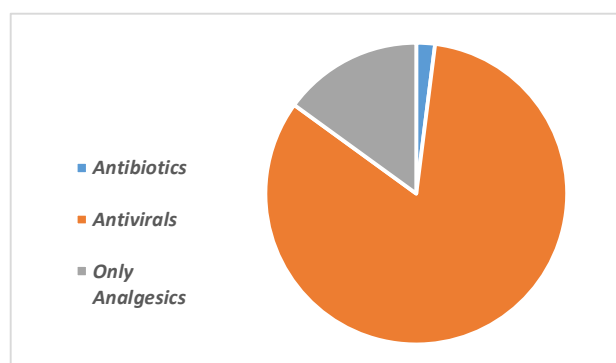


Chart 3: Medications



Discussion

It was found that around 86% of the students are aware of this disease. It is a very well-known disease and it was found that in 1998, an epidemic of EV71 infection caused HFMD and herpangina in thousands of people in Taiwan, including 405 severe cases and 78 deaths (Yu et al., 2020). Due to this epidemic, the existence of this disease was known by the population. However, it was found that only 57% of the students were aware that herpangina had another name. As we all know, herpangina was also referred to as hand, foot, and mouth disease (HFMD). There is still some confusion among the students regarding this fact. It was found that only 55% of the students have correctly identified that this disease mainly affects children, more accurately children less than 6 years old. There has been a case report of herpangina done in Nagpur, India which shows that a total of 4 cases were reported, (2 male and 2 female), all these patients had the classic clinical manifestation of oral and skin lesions. The age group of these patients were 3-4 year old children. (Arora et al., 2008; Saoji, 2008)

It was found that about 89% of the students are aware that herpangina is a viral infection and 89% of the students are aware that this disease can be contagious. Various articles have discussed that this disease is transmitted through the gastrointestinal tract (fecal-oral route) and respiratory route or through contact with an infected person. (Arora et al., 2008; Sarma, 2013) Knowledge regarding what type of infection it is should be known by the students so that they can take preventive measures as these dental students deal with patients day in and day out. 75% of the students have correctly identified the causative organism of this disease which is Group A coxsackieviruses. Knowledge regarding the causative organisms distinguished this disease from other diseases as well as it can help plan the future treatments needed to be taken.

Herpangina can be prevented and about 93% of the students were aware of this fact. A study was done and found that a strong protective effect of hand washing could be expected as the main transmission route is by hand contact. As we know the transmission of herpangina is by ingestion of infected saliva, respiratory droplets or direct contact with fluid from vesicles. Thus, importance regarding the knowledge on how to prevent this disease should be known by the students as we can spread the knowledge to our paediatric patients. 97% of the students

are aware that herpangina shows oral manifestations. It is important for dental students to be aware of diseases that show oral lesions such as herpangina. (Sarma, 2013)

Regarding the management and treatment of herpangina, 53% of the students have stated that there is not antiviral therapy available for this disease and it is true. There are no drugs indicated for Evs. Broad spectrum antiviral drugs are generally given for clinical treatments Antiviral drugs such as acyclovir, ganciclovir and monosodium phosphate vidarabine should not be given to herpangina patients as they are anti-DNA viral drugs which has no effect on RNA viruses However about 83% of the students have chosen antivirals as a choice of medication for herpangina. Even though a specific antiviral therapy was not found for herpangina students should not give any antivirals available. These antivirals have no effect on herpangina. Dental students should be made vigilant about drug prescription as it may have other effects on the patient. Better understanding of the disease will aid its treatment. (Ruan et al., 2011)

Diet plays an important role in treating herpangina and 69% of the students do believe this. The patients are advised to have a light meal, advised not to have any hot, spicy, sour, coarse, hard or irritating foods. Liquid or semi-liquid food at small frequent meals are advised. 79% of the students believe that the use of mouthwashes aids in the treatment of herpangina. Oral care is important as herpangina has many oral manifestations. Lightly salted water or normal saline are recommended for the patients to rinse their mouths after meals These maintain oral hygiene and prevent any other further oral disease and also prevent the spread of the existing disease. (Suzuki et al., 2010)

Conclusion

The awareness about the management strategies of Herpangina among dental students was moderate. Awareness of dental students can always be enhanced by promoting more educational programmes regarding various diseases such as herpangina. It is important as they will play an important role in delivering better health care in the future.

Funding Support

The authors declare that they have no funding support for this study.

Conflict of Interest

The authors declare that they have no conflict of interest.

References

1. Arora, S., Arora, G., & Tewari, V. (2008). Hand foot and mouth disease: Emerging epidemics. In *Indian Journal of Dermatology, Venereology and Leprology* (Vol. 74, Issue 5, p. 503). <https://doi.org/10.4103/0378-6323.44319>

2. Chen, C., Jiang, Q., Song, Z., Li, Y., Wang, H., Lu, Y., Wang, D., Li, M., & Li, T. (2020). Influence of temperature and humidity on hand, foot, and mouth disease in Guangzhou, 2013–2017. In *Journal of International Medical Research* (Vol. 48, Issue 6, p. 030006052092989). <https://doi.org/10.1177/0300060520929895>
3. Duan, X. F., Li, B., Zeng, H. H., Wang, L. H., Qian, C., Chen, F. X., Pang, L., Li, X. W., & Chen, Z. H. (2008). PP-061 Clinical study of patients with hand, foot, and mouth disease associated with aseptic meningitis and encephalitis. In *International Journal of Infectious Diseases* (Vol. 12, p. S74). [https://doi.org/10.1016/s1201-9712\(09\)60212-5](https://doi.org/10.1016/s1201-9712(09)60212-5)
4. Kılınc, F., & Akbaş, A. (2018). Clinical and Demographic Analysis of Patients with Hand, Foot and Mouth Disease Diagnosis. In *Ankara Medical Journal*. <https://doi.org/10.17098/amj.409044>
5. Lalya, I., & Mansouri, H. (2016). Hand-Foot and Mouth syndrome with Capecitabine. In *General Medicine: Open Access* (Vol. 04, Issue 01). <https://doi.org/10.4172/2327-5146.1000i111>
6. Palani, S., Nagarajan, M., Biswas, A. K., Reesu, R., & Paluru, V. (2018). Hand, Foot and Mouth Disease in the Andaman Islands, India. In *Indian Pediatrics* (Vol. 55, Issue 5, pp. 408–410). <https://doi.org/10.1007/s13312-018-1283-7>
7. Palmer, C. R., Richardson, D. M., & Mawson, K. N. (1963). Hand, Foot, and Mouth Disease. In *BMJ* (Vol. 2, Issue 5372, pp. 1591–1592). <https://doi.org/10.1136/bmj.2.5372.1591-c>
8. Pongsumpun, P., & Wongvanich, N. (2018). Age Structural Model of the Hand Foot Mouth Disease in Thailand. In *2018 2nd European Conference on Electrical Engineering and Computer Science (EECS)*. <https://doi.org/10.1109/eecs.2018.00033>
9. Repass, G. L., Palmer, W. C., & Stancampiano, F. F. (2014). Hand, foot, and mouth disease: identifying and managing an acute viral syndrome. *Cleveland Clinic Journal of Medicine*, 81(9), 537–543.
10. Ruan, F., Yang, T., Ma, H., Jin, Y., Song, S., Fontaine, R. E., & Zhu, B.-P. (2011). Risk Factors for Hand, Foot, and Mouth Disease and Herpangina and the Preventive Effect of Hand-washing. In *PEDIATRICS* (Vol. 127, Issue 4, pp. e898–e904). <https://doi.org/10.1542/peds.2010-1497>
11. Saoji, V. A. (2008). Hand, foot and mouth disease in Nagpur. *Indian Journal of Dermatology, Venereology and Leprology*, 74(2), 133–135.
12. Sarma, N. (2013). Hand, foot, and mouth disease: Current scenario and Indian perspective. In *Indian Journal of Dermatology, Venereology, and Leprology* (Vol. 79, Issue 2, p. 165). <https://doi.org/10.4103/0378-6323.107631>
13. Suzuki, Y., Taya, K., Nakashima, K., Ohyama, T., Kobayashi, J. M., Ohkusa, Y., & Okabe, N. (2010). Risk factors for severe hand foot and mouth disease. In *Pediatrics International* (Vol. 52, Issue 2, pp. 203–207). <https://doi.org/10.1111/j.1442-200x.2009.02937.x>
14. Woodland, D. L. (2019). Hand, Foot, and Mouth Disease. In *Viral Immunology* (Vol. 32, Issue 4, pp. 159–159). <https://doi.org/10.1089/vim.2019.29037.dlw>
15. Yu, H., Li, X.-W., Liu, Q.-B., Deng, H.-L., Liu, G., Jiang, R.-M., Deng, J.-K., Ye, Y.-Z., Hao, J.-H., Chen, Y.-H., Nong, G.-M., Shen, Z.-B., Liu, C.-S., Zou, Y.-X., Wu, J.-Z., Wu, X.-D., Chen, B.-Q., Luo, R.-P., Lin, A.-W., ... Liu, X.-D. (2020). Diagnosis and treatment of herpangina: Chinese expert consensus. In *World Journal of Pediatrics* (Vol. 16, Issue 2, pp. 129–134). <https://doi.org/10.1007/s12519-019-00277-9>

16. Zhang, J., Kang, Y., Yang, Y., & Qiu, P. (2015). Statistical monitoring of the hand, foot and mouth disease in China. In *Biometrics* (Vol. 71, Issue 3, pp. 841–850). <https://doi.org/10.1111/biom.12301>