

ANALYSIS OF MB-2 CANAL IN MAXILLARY MOLARS - A RETROSPECTIVE STUDY

G J.Chandra Pooja¹, Sowmya K², Ganesh Jeevanandan³

Abstract

The second mesiobuccal canal in mesiobuccal roots of maxillary molars is a common finding during root canal treatment. Inability to locate this canal can lead to failure of root canal treatment in maxillary molars. Several in vitro and in vivo studies have been used to assess its prevalence, with the variations according to the methodology applied, along with the population of interest. The aim of the study was to evaluate the number and occurrence of MB-2 canal in male and female patients in Saveetha Dental College. A retrospective study was carried out using digital records of 1269 patients who reported to the Department of Endodontics from June 2019 to March 2020. The data of patients with MB-2 canal variations were collected from the patient records. The following data were retrieved from the dental records: patient age, gender, and teeth number. The coding was done in MS excel and data was transferred to a host computer and processed using SPSS software version 20.0 (SPSS Inc., Chicago, IL, USA). Descriptive statistics was used to study the data collected and to analyse frequency distribution. Chi square test was used to assess the association at 5% significance level ($P < 0.05$). The results showed significant association of occurrence of MB-2 canal with age and teeth number but not with gender. The highest percentage of MB-2 canals was seen among male patients (51.39%), in maxillary first molars (84.74%) and in people below 30 years of age (52.78%).

Keywords: ; CBCT; maxillary molar; MB-2 canal; root canal treatment

Introduction

Dental caries that begin as an incipient lesion, traumatic injuries [1] and non carious lesions, when present deep and close to the pulp can cause inflammation and infection of the pulp [2-4]. Such teeth require root canal treatment followed by a permanent restoration for saving the tooth [5-7].

The cleaning and shaping of root canal space is one of the most important and fundamental aspects of endodontic therapy [8]. The major hurdle in root canal disinfection is the removal of the bacterial biofilm. The only way to achieve optimal removal is by following a proper

¹ Saveetha Dental College and Hospitals, Saveetha Institute of Medical and Technical Sciences, Saveetha University, Chennai, India, Email: 151501060.sdc@saveetha.com

² Senior lecturer, Department Of Conservative dentistry and Endodontics, Saveetha Dental College and Hospitals, Saveetha Institute of Medical and Technical Sciences, Saveetha University, Chennai, India, Email: sowmyak.sdc@saveetha.com

³ Reader, Department of Pedodontics, Saveetha Dental College and Hospitals, Saveetha Institute of Medical and Technical Sciences, Saveetha University, Chennai, India, Email: ganesh.sdc@saveetha.com

irrigation protocol and final irrigant activation [9]. Complete debridement, disinfection of the pulpal space are considered to be essential for predictable long term success in endodontic treatment[10,11].

Most of the areas of the root canal wall that remain untouched by the instruments and medicaments harbours debris of tissues, microbes, and their by-products and can result in reinfection or persistent periradicular inflammation [12]. This emphasises the importance of cleaning and disinfecting all the root canals to prevent the failure of root canal treatment [13].

Maxillary molar is the tooth with the largest volume and most complex root and root canal anatomy, also possibly the most treated and least understood posterior tooth [14]. Maxillary molars are known to have a fourth canal [second mesio buccal canal] located in the mesio buccal root [15]. MB-2 canals which are difficult to find are considered one of the biggest mysteries in endodontics. It has been suggested that endodontically retreated teeth contain more undetected MB-2 canal than 1st time treated teeth, suggesting that failure to locate, debride and fill existing MB-2 canals leads to poor prognosis [16]. Weine stated that one of the reasons for the failure of endodontic treatment of maxillary molars is due to failure to locate and fill the second mesio buccal canal [17]. Improper knowledge of anatomy of the teeth may lead to iatrogenic causes such as the degree of dentin removed during operative procedures or root canal preparation, dentinal defects induced during instrumentation which are also suggested as predisposing factors for vertical root fracture and since maximum masticatory forces act on the posterior teeth [18,19]. Therefore it is of major importance to have thorough knowledge of dental anatomy and its variation prior to initiator of treatment.

A conventional preoperative radiograph does not always give a clear idea of an extra canal. Hence multiple preoperative radiographs in various angulations must be taken. Mechanical instrumentation alone may not be sufficient to remove bacteria and necrotic tissue from root canals owing to the complex anatomy hence irrigants play a crucial role in debridement and disinfection of the root canal space [20].

Location and treatment of second mesiobuccal canal of maxillary first molars have been aided by modification in endodontic access and detection techniques along with advancements in illumination and magnification technology [21]. Several studies using micro computed tomography scanning have shown that most of the areas of main root canal wall remain untouched by the instruments. By magnifying and illuminating the grooves is the pulpal floor and differentiating the colour differences between the dentine of the floor and wall the surgical operating microscope, had made canal location easier [22,23].

Many factors such as experience and knowledge of the operator and devices that are used during root canal treatment such as magnification devices and CBCT affect the occurrence of MB-2 canal [24-28]. The aim of the study was to analyse the number of MB-2 canals identified during root canal treatment of maxillary molar and its association with age and gender.

MATERIALS AND METHOD

Study setting

In this retrospective study, data of 1269 patients who underwent root canal treatment in maxillary molars were collected from dental records. At data extraction, all information was anonymized and tabulated onto a spreadsheet. The study was commenced after approval from the Institutional Review Board. The ethical approval number for the study was SDC / SIHEC / 2020 / DIASDATA / 0619 - 0320.

Data collection and / tabulation

To fulfil the inclusion criteria, patients who underwent root canal treatment in upper molars were included in the study. Root canal retreatment cases, incomplete treatment and cases with iatrogenic errors were excluded. The presence of MB-2 canal was verified with both picture of access cavity and post operative radiograph.

Sampling

Data were collected from June 2019 to March 2020 for 1269 patients who underwent root canal treatment in maxillary molars. The following data were retrieved from the dental records: patient age, gender, and teeth number and were analysed.

Statistical analysis

The data was transferred to a host computer and processed using SPSS software version 20.0 (SPSS Inc., Chicago, IL, USA). Descriptive statistics and Chi square test was used to compare the occurrence of MB-2 canal with age, gender teeth number of the patient. The significance level was set at 5%.

RESULTS

A total of 1296 maxillary molars that underwent root canal treatment were evaluated. Among all the teeth evaluated, only 5.67% of the maxillary molars had MB-2 canal [Figure 1]. MB-2 canal was found more commonly in the age group less than 30 (52.78%) followed by the 31-60 years (44.44%) group and the least in the age group above 60 years (2.78%) [Figure 2]. MB-2 was found more commonly in males (51.39%) than females (48.61%) [Figure 3]. Among the different teeth, 84.74% of MB-2 canal was found in maxillary first molars and 15.28% was found in maxillary second molars [Figure 4]. MB-2 canals were not found in maxillary third molars. Chi-square test was done to evaluate the association between the occurrence of MB-2 canal with age, gender and teeth number. There was significant association between occurrence of MB-2 canal and age (P value- 0.031; Chi square test) [Figure 5] and teeth number (P value- 0.025; Chi square test) [Figure 7]. No significant association was seen between occurrence of MB-2 canal and gender (P value- 0.55; Chi square test) [Figure 6].

DISCUSSION

One of the commonly missed canal during root canal treatment is the second mesiobuccal canal in the maxillary first molar [29,30]. The complexity of the root canal system is linked with the frequency and risk of missed anatomy. This is especially true when working on molars. Failure to locate and treat all the canals may lead to colonization of microorganisms and failure of root canal treatment[27,31].

The present study describes prevalence of second mesiobuccal canal in maxillary molars among different age, gender and teeth numbers in the Chennai population visiting a private dental college.

In our study, out of the total sample size, 5.67% of teeth had MB-2 canal [Figure 1]. The percentage of MB-2 canal found in this study is lesser compared to other studies [32]. This could be due to the small sample size, study population, study design and CBCT not being used.

The results of our study shows that occurrence of MB-2 canal was more among the patients below 30 years of age (2.78%) [Figure 2]. The results of this study was similar to Radhika Kewalramani's [33] study which stated that the prevalence of MB-2 was highest in the 20-40 years age group [67.4%] followed by >40 years [57.5%] and < 20 years [50.6%]. The study also states that the low prevalence in <20year age group can be attributed to presence of single wide mesiobuccal orifice. As a person ages, a septum of secondary dentin is formed that divides the single wide orifice into two separate orifices. Hence, in young individuals, these canals are regarded as 'ribbon shaped' canal, rather than two canals. In >40 years age group, decreased prevalence was observed in our study. It may be due to the fact that in this age group many MB-2 canals were not seen at 2 mm level but were present at more apical levels [33].

The study results shows [Figure 2] that the occurrence of MB-2 canal was more in male patients compared to female patients. This is consistent with what was reported by Lee et al. [34], who found a greater frequency of the MB-2 canal in men (48.7%) than in women (30.8%), and is similar to what was reported by Pablo Betancourt [35] who said that the prevalence was greater in men (63%) than in women (37%).

The prevalence of MB-2 was found more in maxillary first molar compared to the other two molars [Figure 4] which was similar to the results of Pablo Betancourt where MB-2 canal was found in 69.82% of the 1st maxillary molar and 46.91% of 2nd maxillary molar [35]. Zhang et al found 52% of MB-2 canals in maxillary first molars and 22% of MB-2 canals in maxillary second molars, [32] while other studies found MB-2 canals in 74.5% and 57.8% of first and second maxillary in an Egyptian population; 73.6% and 56.2% in the Thai population; and 87.2% and 47.3% in the Spanish population, respectively [36-38]. A recent systematic review has pointed to the presence of MB-2 canals in 59.3% of maxillary first molars when CBCT is used for assessment [39].

The results of our study show [Figure 5] significant association between age of the patient and MB-2 canal (p value-0.031< 0.05; Chi square test). Maxillary molars without an MB-2 canal were more than teeth with MB-2

canal present across all the age groups. The results of the study were similar to Radhika Kewalramani's [33] study which says that the difference in the prevalence distribution of MB-2 canal among different age groups was statistically significant.

Gender had no association with occurrence of MB-2 canal (p value-0.55 > 0.05; Chi square test) [Figure 6], which was similar to the results of Fouad Abduljabbar et al which states prevalence of MB-2 canal in first maxillary molars has no significant difference in males and females [40]. Maxillary molars without an MB-2 canal were more than teeth with an MB-2 canal present for both males and females. And a study by Suroopa Das et al [41] which states that second mesiobuccal canals were detected in 73% and 71% of maxillary molars of males and females, respectively, indicating no significant difference between genders.

Teeth number had association with occurrence of MB-2 canal (p value- 0.025 < 0.05; Chi square test) [Figure 7] which was similar to a study by Li Ting Tzeng et al [42] which showed the number of patients having bilateral maxillary first molars with additional root canals in MB roots was 277 (77.80%). The number of patients having bilateral maxillary second molars with additional root canals in MB roots was 141 (35.97%).

The limitations of the study include small sample size and geographic isolation. CBCT analysis is required to corroborate the clinical findings. Future clinical studies must include a wider population, larger sample size and CBCT imaging.

CONCLUSION

Within the limitation of the study age MB-2 canals are seen more in males and patients younger than 30 years of age and is more common in maxillary first molars. Having a proper knowledge of prevalence and distribution pattern of canal orifices on the pulpal floor helps the clinicals quick identification and location. It helps the clinician to perform the endodontic treatment safely, effectively and productively.

ACKNOWLEDGEMENT

The authors are thankful to the Director of Saveetha Dental College And Hospital, Chennai.

AUTHORS CONTRIBUTION

J. ChandraPooja , Dr Sowmya K were the main contributors to the concept, design, literature analysis, workshop discussions, and drafting and revising manuscript. Dr Sowmya K and Dr Ganesh Jeevanandhan contributed to drafting and revising manuscripts. All authors gave final approval of the version to be published.

CONFLICTS OF INTEREST

There were no conflicts of interest.

REFERENCE

1. Rajakeerthi R, Ms N. Natural Product as the Storage medium for an avulsed tooth--A Systematic Review. *Cumhuriyet Dental Journal*. 2019;22(2):249–56.
2. Nasim I, Hussainy S, Thomas T, Ranjan M. Clinical performance of resin-modified glass ionomer cement, flowable composite, and polyacid-modified resin composite in noncarious cervical lesions: One-year follow-up [Internet]. Vol. 21, *Journal of Conservative Dentistry*. 2018. p. 510. Available from: http://dx.doi.org/10.4103/jcd.jcd_51_18
3. Nandakumar M, Nasim I. Comparative evaluation of grape seed and cranberry extracts in preventing enamel erosion: An optical emission spectrometric analysis. *J Conserv Dent*. 2018 Sep;21(5):516–20.
4. Janani K, Palanivelu A, Sandhya R. Diagnostic accuracy of dental pulse oximeter with customized sensor holder, thermal test and electric pulp test for the evaluation of pulp vitality: an in vivo study. *Brazilian*

- Dental Science. 2020;23(1):8.
5. Ravinthar K, Others. Recent advancements in laminates and veneers in dentistry. *Research Journal of Pharmacy and Technology*. 2018;11(2):785–7.
 6. Jose J, Subbaiyan H. Different Treatment Modalities followed by Dental Practitioners for Ellis Class 2 Fracture–A Questionnaire-based Survey. *Open Dent J* [Internet]. 2020; Available from: <https://opendentistryjournal.com/VOLUME/14/PAGE/59/FULLTEXT/>
 7. Rajendran R, Kunjusankaran RN, Sandhya R, Anilkumar A, Santhosh R, Patil SR. Comparative Evaluation of Remineralizing Potential of a Paste Containing Bioactive Glass and a Topical Cream Containing Casein Phosphopeptide-Amorphous Calcium Phosphate: An in Vitro Study. *Pesqui Bras Odontopediatria Clin Integr* [Internet]. 2019;19. Available from: http://www.scielo.br/scielo.php?pid=S1983-46322019000100364&script=sci_arttext
 8. Ramanathan S, Solete P. Cone-beam Computed Tomography Evaluation of Root Canal Preparation using Various Rotary Instruments: An in vitro Study. *J Contemp Dent Pract*. 2015 Nov 1;16(11):869–72.
 9. Teja KV, Ramesh S. Shape optimal and clean more. *Saudi Endodontic Journal*. 2019 Sep 1;9(3):235.
 10. Noor S, Others. Chlorhexidine: Its properties and effects. *Research Journal of Pharmacy and Technology*. 2016;9(10):1755–60.
 11. Manohar MP, Sharma S. A survey of the knowledge, attitude, and awareness about the principal choice of intracanal medicaments among the general dental practitioners and nonendodontic specialists. *Indian J Dent Res*. 2018 Nov;29(6):716–20.
 12. Teja KV, Ramesh S, Priya V. Regulation of matrix metalloproteinase-3 gene expression in inflammation: A molecular study. *J Conserv Dent*. 2018 Nov;21(6):592–6.
 13. Ramamoorthi S, Nivedhitha MS, Divyanand MJ. Comparative evaluation of postoperative pain after using endodontic needle and EndoActivator during root canal irrigation: A randomised controlled trial. *Aust Endod J*. 2015 Aug;41(2):78–87.
 14. Burns RC. Access openings and tooth morphology: Cohen’s pathways of pulp. St Louis, Mo, USA: The Mosby Co; 2002.
 15. Baratto-Filho F, Fariniuk LF, Ferreira EL, Pecora JD, Cruz-Filho AM, Sousa-Neto MD. Clinical and macroscopic study of maxillary molars with two palatal roots. *Int Endod J*. 2002 Sep;35(9):796–801.
 16. Wolcott J, Ishley D, Kennedy W, Johnson S, Minnich S. Clinical Investigation of Second Mesio Buccal Canals in Endodontically Treated and Retreated Maxillary Molars [Internet]. Vol. 28, *Journal of Endodontics*. 2002. p. 477–9. Available from: <http://dx.doi.org/10.1097/00004770-200206000-00016>
 17. Weine FS, Smulson MH, Herschman JB. *Endodontic therapy*. ed. St Louis: Mosby. 1996;640–1.
 18. Kumar SA, Ajitha P. Evaluation of compressive strength between Cention N and high copper amalgam- An in vitro study. *Drug Invention Today* [Internet]. 2019;12(2). Available from: <http://search.ebscohost.com/login.aspx?direct=true&profile=ehost&scope=site&authtype=crawler&jrnl=09757619&AN=135073030&h=EPshB%2BWdMW6RORQsgsi7kDSCHR%2FdPfdyd5cg6D2eDJU793RiHquNyxVCqwt7W935rr7wa10q97JQtzs1ihD2bQ%3D%3D&cr1=c>
 19. Kumar D, Antony S. Calcified Canal and Negotiation-A Review. *Research Journal of Pharmacy and Technology*. 2018;11(8):3727–30.
 20. Siddique R, Sureshbabu NM, Somasundaram J, Jacob B, Selvam D. Qualitative and quantitative analysis of precipitate formation following interaction of chlorhexidine with sodium hypochlorite, neem, and tulsi. *J Conserv Dent*. 2019 Jan;22(1):40–7.

21. Weller RN, Hartwell GR. The impact of improved access and searching techniques on detection of the mesiolingual canal in maxillary molars. *J Endod.* 1989 Feb;15(2):82–3.
22. Kim S, Baek S. The microscope and endodontics. *Dent Clin North Am.* 2004 Jan;48(1):11–8.
23. Carr GB, Murgel CAF. The use of the operating microscope in endodontics. *Dent Clin North Am.* 2010;54(2):191–214.
24. Pattanshetti N, Gaidhane M, Al Kandari AM. Root and canal morphology of the mesiobuccal and distal roots of permanent first molars in a Kuwait population--a clinical study. *Int Endod J.* 2008;41(9):755–62.
25. Stropko JJ. Canal morphology of maxillary molars: clinical observations of canal configurations. *J Endod.* 1999 Jun;25(6):446–50.
26. Kulid JC, Peters DD. Incidence and configuration of canal systems in the mesiobuccal root of Maxillary first and second molars [Internet]. Vol. 16, *Journal of Endodontics.* 1990. p. 311–7. Available from: [http://dx.doi.org/10.1016/s0099-2399\(06\)81940-0](http://dx.doi.org/10.1016/s0099-2399(06)81940-0)
27. Fogel HM, Peikoff MD, Christie WH. Canal configuration in the mesiobuccal root of the maxillary first molar: a clinical study. *J Endod.* 1994 Mar;20(3):135–7.
28. Gilles J, Reader A. An SEM investigation of the mesiolingual canal in human maxillary first and second molars. *Oral Surg Oral Med Oral Pathol.* 1990 Nov;70(5):638–43.
29. Witherspoon DE, Small JC, Regan JD. Missed canal systems are the most likely basis for endodontic retreatment of molars. *Tex Dent J.* 2013 Feb;130(2):127–39.
30. Cantatore G, Berutti E, Castellucci A. Missed anatomy: frequency and clinical impact. *Endodontic Topics.* 2006 Nov;15(1):3–31.
31. Görduysus MO, Görduysus M, Friedman S. Operating microscope improves negotiation of second mesiobuccal canals in maxillary molars. *J Endod.* 2001 Nov;27(11):683–6.
32. Zhang R, Yang H, Yu X, Wang H, Hu T, Dummer PMH. Use of CBCT to identify the morphology of maxillary permanent molar teeth in a Chinese subpopulation. *Int Endod J.* 2011 Feb;44(2):162–9.
33. Kewalramani R, Murthy CS, Gupta R. The second mesiobuccal canal in three-rooted maxillary first molar of Karnataka Indian sub-populations: A cone-beam computed tomography study. *J Oral Biol Craniofac Res.* 2019 Oct;9(4):347–51.
34. Lee J-H, Kim K-D, Lee J-K, Park W, Jeong JS, Lee Y, et al. Mesiobuccal root canal anatomy of Korean maxillary first and second molars by cone-beam computed tomography. *Oral Surg Oral Med Oral Pathol Oral Radiol Endod.* 2011 Jun;111(6):785–91.
35. Betancourt P, Navarro P, Cantín M, Fuentes R. Cone-beam computed tomography study of prevalence and location of MB2 canal in the mesiobuccal root of the maxillary second molar. *Int J Clin Exp Med.* 2015 Jun 15;8(6):9128–34.
36. Ghobashy AM, Nagy MM, Bayoumi AA. Evaluation of Root and Canal Morphology of Maxillary Permanent Molars in an Egyptian Population by Cone-beam Computed Tomography. *J Endod.* 2017 Jul;43(7):1089–92.
37. Ratanajirasut R, Panichuttra A, Panmekiate S. A Cone-beam Computed Tomographic Study of Root and Canal Morphology of Maxillary First and Second Permanent Molars in a Thai Population. *J Endod.* 2018 Jan;44(1):56–61.
38. Pérez-Heredia M, Ferrer-Luque CM, Bravo M. Cone-beam computed tomographic study of root anatomy and canal configuration of molars in a Spanish population. *Journal of [Internet].* 2017; Available from: <https://www.sciencedirect.com/science/article/pii/S009923991730362X>

39. Corbella S, Del Fabbro M, Tsesis I, Taschieri S. Computerized tomography technique for the investigation of the maxillary first molar mesiobuccal root. *Int J Dent.* 2013 Sep 8;2013:614898.
40. Abduljabbar F, Others. Long Term Study of the Prevalence of Second Mesiobuccal canal in Maxillary First Molar of Saudi Population. *EC Dental Science.* 2019;18:1014–20.
41. Das S, Warhadpande MM, Redij SA, Jibhkate NG, Sabir H. Frequency of second mesiobuccal canal in permanent maxillary first molars using the operating microscope and selective dentin removal: A clinical study. *Contemp Clin Dent.* 2015 Jan;6(1):74–8.
42. Farhat Yaasmeen Sadique Basha, Rajeshkumar S, Lakshmi T, Anti-inflammatory activity of *Myristica fragrans* extract . *Int. J. Res. Pharm. Sci.,* 2019 ;10(4), 3118-3120 DOI: <https://doi.org/10.26452/ijrps.v10i4.1607>
43. Tzeng L-T, Chang M-C, Chang S-H, Huang C-C, Chen Y-J, Jeng J-H. Analysis of root canal system of maxillary first and second molars and their correlations by cone beam computed tomography. *J Formos Med Assoc.* 2020 May;119(5):968–73.

GRAPHS

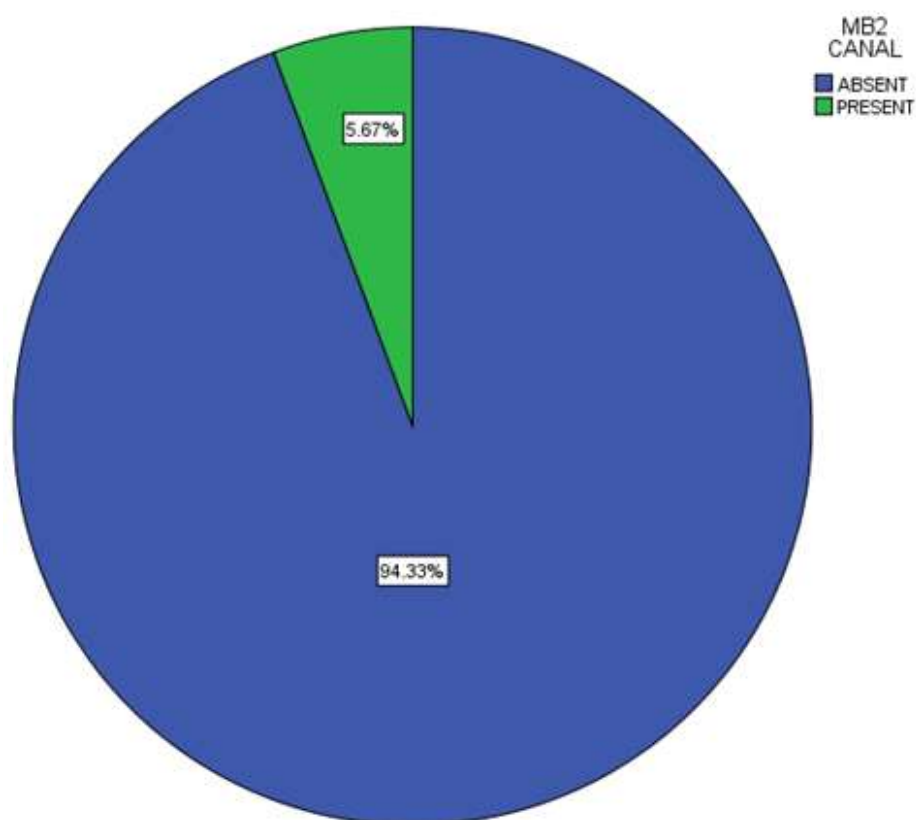


Figure 1: Pie chart representing prevalence of MB-2 canals. The green colour shows the percentage of MB-2 canal present which was 5.67% and the blue colour shows percentage of teeth without MB-2 canal which was 94.33%.

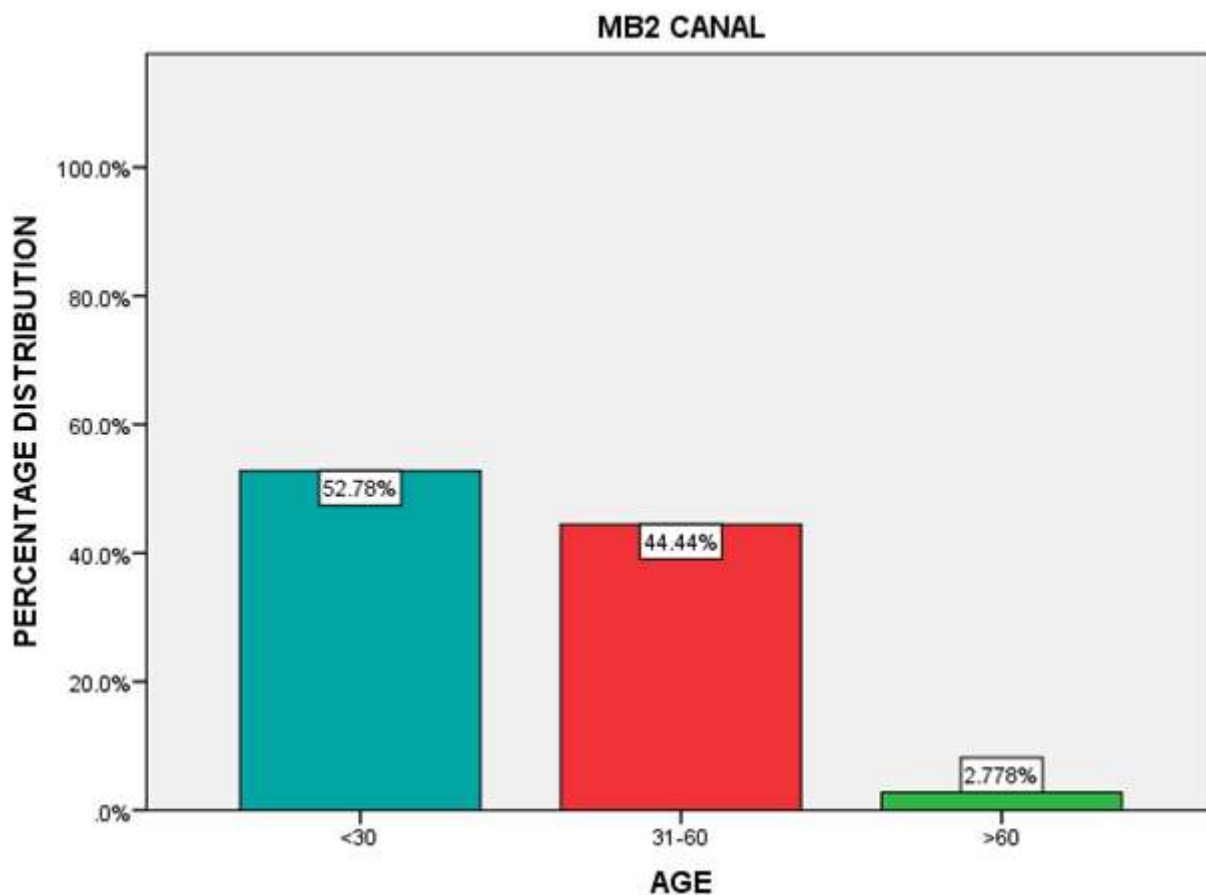


Figure 2 : Bar diagram representing distribution of MB-2 canals according to age. X-Axis represents the age group and Y-axis represents the percentage distribution of MB-2 canal. The percentage distribution shows 52.78% of MB-2 canals were seen in the less than 30 years age group (Blue), 44.44% in the 31-60 years age group (Red) and 2.78% were seen in age group above 60 years (Green), with the highest number of MB-2 occurring in patients below 30 years (52.78%).

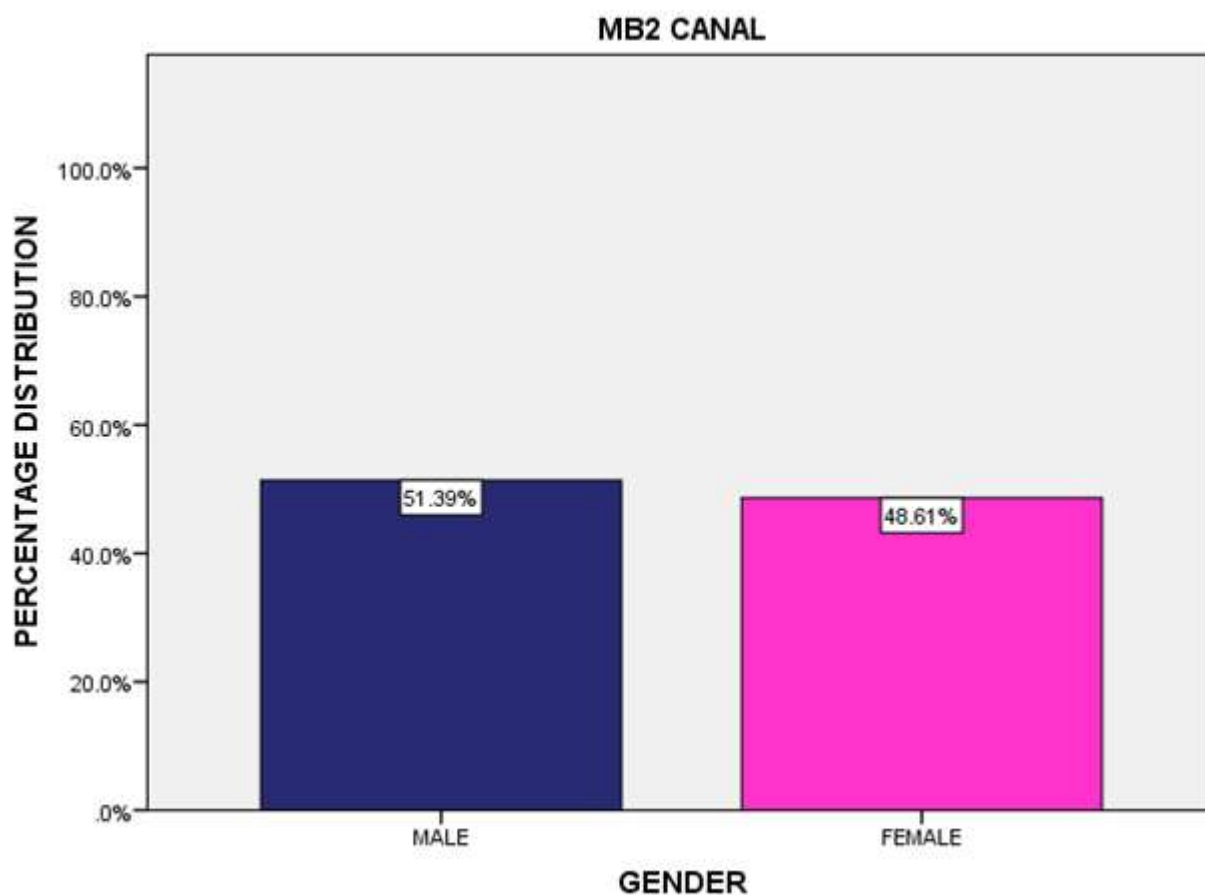


Figure 3 : Bar diagram representing distribution of MB-2 canals according to gender. X-Axis represents the gender of the patient and Y axis represents the percentage distribution of MB-2 canal. The graph shows 51.39% of MB-2 canal present in male patients (Dark blue) and 48.61% in female patients (Pink), with a maximum number of MB-2 canal seen in male patients(51.39%).

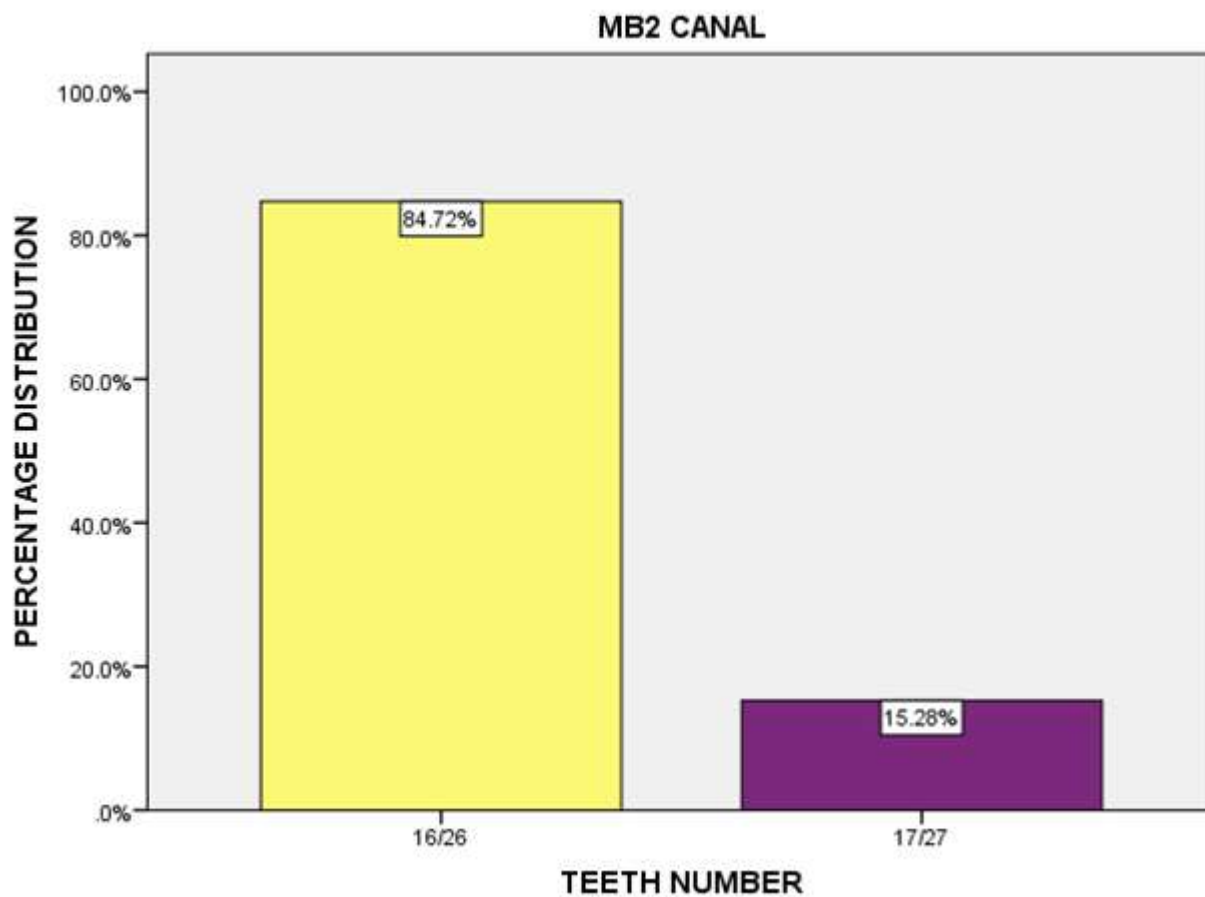


Figure 4 : Bar diagram representing distribution of MB-2 canals according to teeth number. X-Axis represents the tooth number and Y axis represents the percentage distribution of MB-2 canal. Yellow colour represents the percentage of MB-2 canal occurrence in 16/26 (84.72%) and purple colour represents the percentage of MB-2 canal occurrence in 17/27 (15.28%) .With the highest number of MB-2 occurring in maxillary first molars (84.72%).

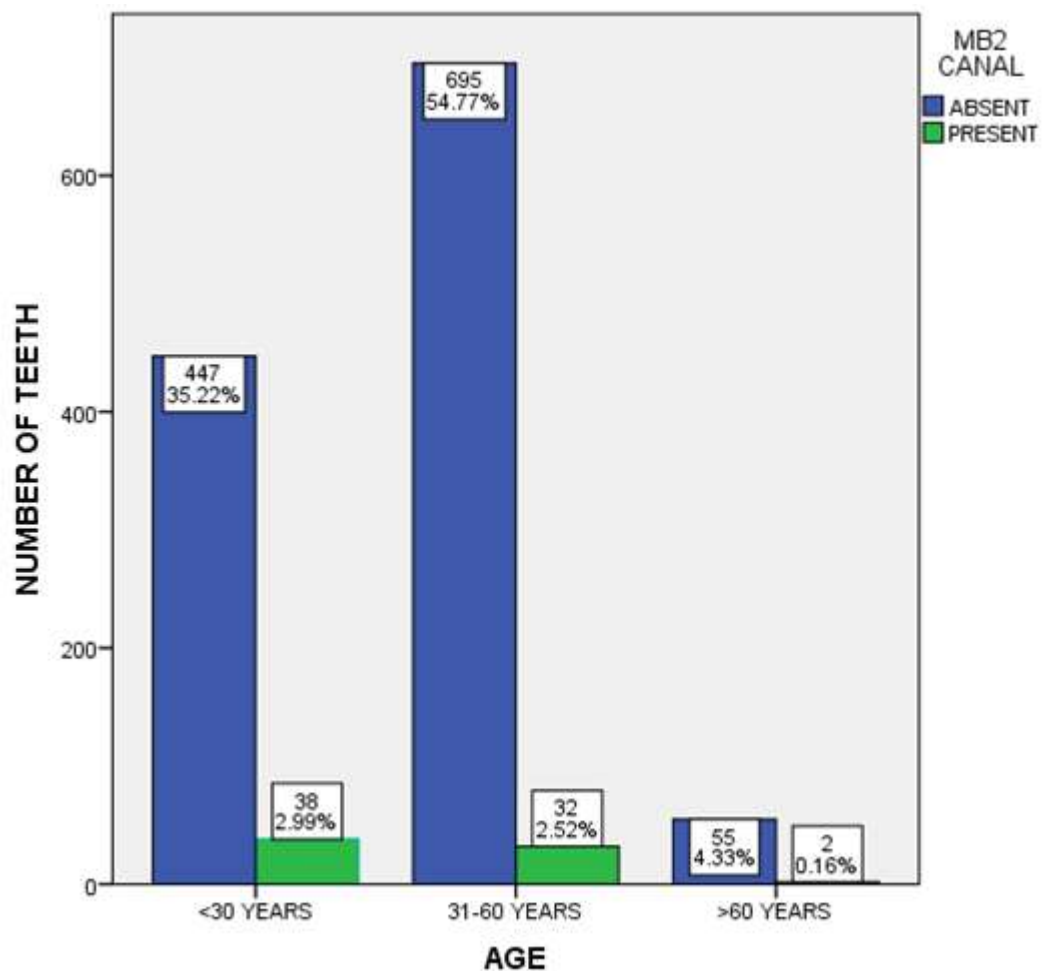


Figure 5 : Bar diagram representing association between the occurrence of MB-2 canal and age of the patients. X-axis represents the age of the patient and Y-axis represents the number of patients. MB-2 canal occurred most among the patients under 30 years (2.99%). The association between the occurrence of MB-2 canal and the age of the patients was found to be statistically significant (Pearson's chi square value-6.931, df -4, p value = 0.031).

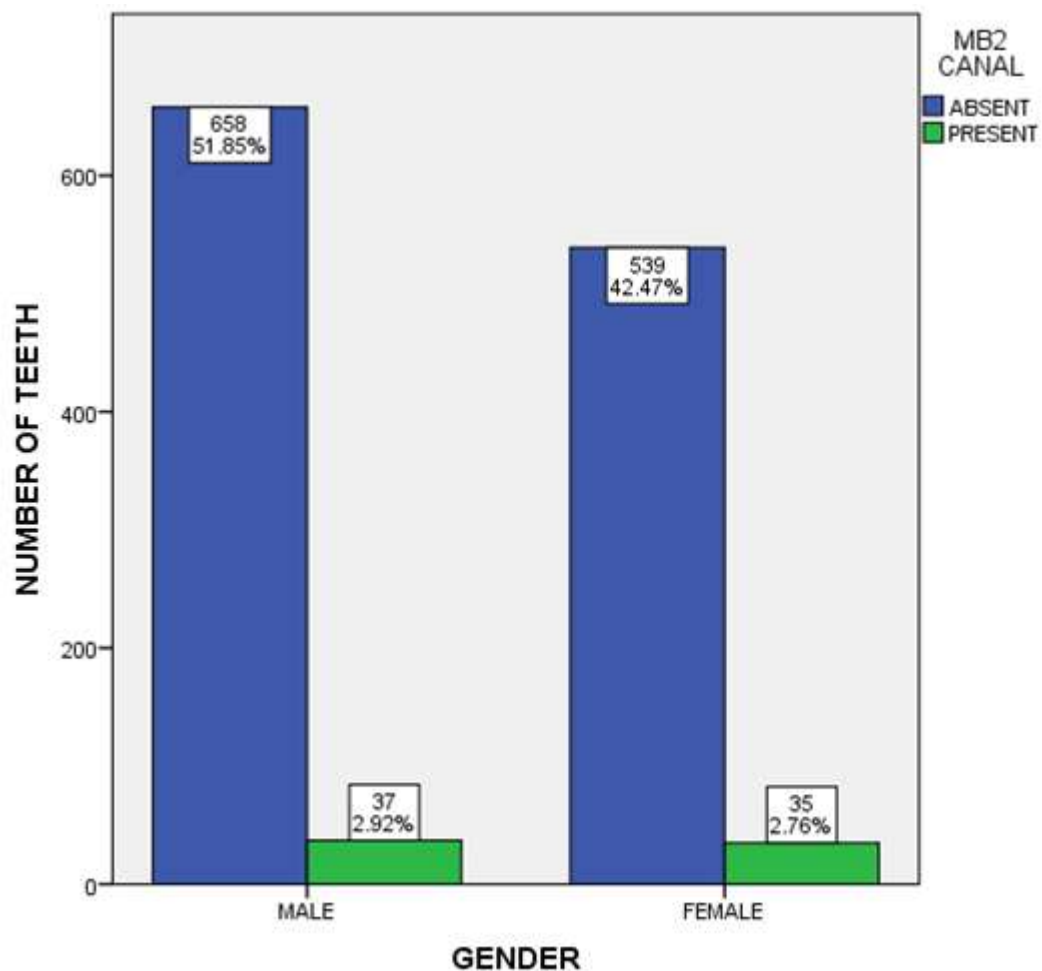


Figure 6 : Bar diagram representing association between the occurrence of MB-2 canal and gender of the patients. X-axis represents the gender of the patient and Y-axis represents the number of patients. MB-2 canal occurred most among the male patients (2.92%). The association between the occurrence of MB-2 canal and the gender of the patients was found to be statistically not significant (Pearson's chi square value-0.352, df -1, p value = 0.55).

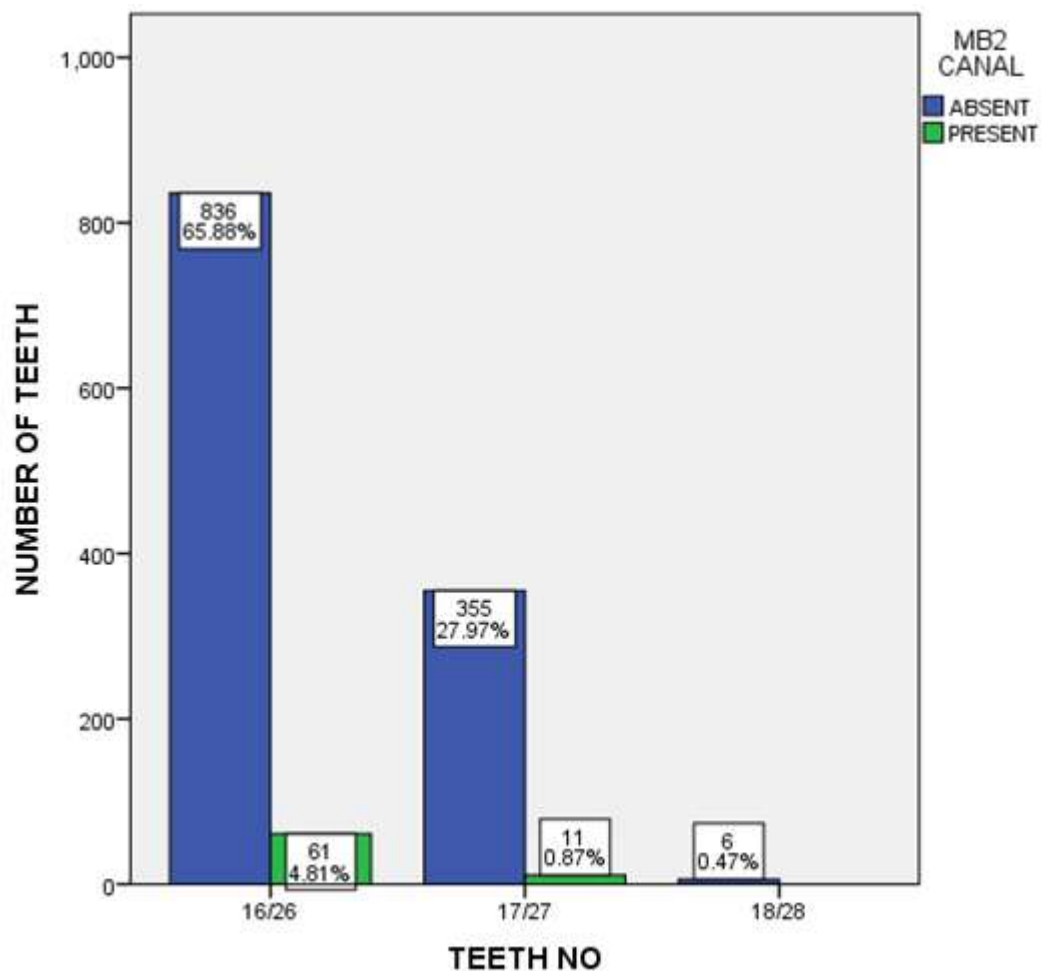


Figure 7 : Bar diagram representing association between the occurrence of MB-2 canal and teeth number. X-axis represents the teeth number and Y-axis represents the number of patients. The MB-2 canal was found most in 16/26 (4.81%). The association between the occurrence of MB-2 canal and teeth number was found to be statistically significant (Pearson's chi square value-7.352, df -2, p value = 0.025).