

KNOWLEDGE ATTITUDE AND PRACTICE SURVEY ON MANAGEMENT OF NECROTIC IMMATURE PERMANENT TEETH

Abhishek naram¹, Deepak.S²

Abstract

Necrotic immature permanent tooth presents a distinctive challenge for the endodontist. Various treatment modalities have been employed to create hard tissue barriers at the apex, Regenerative endodontics is a novel modality which involves physiological replacement of the damaged structures of tooth like dentin, root and cells of the pulp-dentin complex. The aim of this survey was to study the level of awareness, current state of knowledge and opinions towards management of immature necrotic permanent teeth amongst the dental students. An online survey was done with the structured questionnaire based on knowledge, attitude, practice and it was distributed among 100 undergraduate students via electronic media. Data entry was done in the Excel sheet and SPSS software was used to analyze the data. The descriptive statistics were used to determine the responses given by the participants. We received 100 responses from the participants; the majority of the participants are interns (50%). The data from this survey revealed inadequate knowledge of dental students towards management of immature necrotic permanent teeth. Moreover, there is a need to conduct more seminars, CDE and workshop programmes to improve knowledge regarding management of necrotic immature permanent teeth.

Keywords: *Apexification; Regenerative endodontics; Revascularization; Stem cells.*

I. Introduction

Necrotic immature permanent tooth presents a distinctive challenge for the endodontist. Various treatment modalities have been employed to create a hard tissue barrier at the apex, which includes non-vital pulp therapy with calcium hydroxide, apexification with mineral trioxide aggregate, pulp revascularization and regeneration [1].

Regenerative endodontics is a novel modality which involves physiological replacement of the damaged structures of teeth like dentin, root and cells of the pulp-dentin complex. Numerous published case reports have revealed increased dentinal wall thickness, continued root development and apical closure, but there is still lack of sound scientific evidence regarding histological nature of the type of tissue [1]

¹ Saveetha dental college and hospitals, Saveetha Institute of Medical and Technical Sciences, Saveetha University, Chennai, Tamilnadu, India, abhishekreddynaram@gmail.com

² Corresponding author: Senior lecturer, Department of Conservative Dentistry and Endodontics, Saveetha dental college and hospitals, Saveetha Institute of Medical and Technical Sciences, Saveetha University, Chennai, Tamilnadu, India, deepaks.sdc@saveetha.com

Permanent immature teeth with necrotic pulp and periapical disease is a constant problem and area of keen interest for endodontists [1]. Disinfection of root canal space is difficult to achieve in these teeth with endodontic files using standard protocol. Another difficulty arises during root canal filling due to lack of apical barrier in open apex and its impingement on periodontal tissues [2]. Even if these challenges are faced and sorted out, the roots of these teeth are very thin that constitute a high risk of fracture [3]. Various treatment modalities have been described in literature to create a hard tissue barrier at the apex, which includes non-vital pulp therapy with calcium hydroxide, apexification with mineral trioxide aggregate (MTA), pulp revascularization and regeneration [3,4].

The traditional non-vital pulp (NVP) therapy with calcium hydroxide (Ca(OH)₂) has been studied largely and is reported to have a good outcome [5]. However, there are certain limitations associated with this technique [6]. The principal drawback is the long duration of about 6 and 18 months required for the formation of hard tissue apical barrier and required follow-ups every 3 months to check the progression of barrier formation [7]. Patient compliance is extremely important for the completion of the procedure. This technique also tends to decrease the fracture resistance of the root dentine [8]. Thus there is always a possibility of root fracture before hard tissue formation [9]. Kahler et al. recently reported that tendency to root fracture is more related to the stage of root development rather than long-term Ca(OH)₂ use [8].

Apexification with MTA has also gained popularity among clinicians which is relatively easy and less time-consuming, but lacks regenerative capability and long-term survival is also guarded due to reduced fracture resistance [10]. Conventional root canal therapy (RCT) and apexification can only provide apical barrier, but possibility of reinfections and tooth fractures are very undesirable and disappointing for patients and practitioners [11].

Recently, regenerative endodontics has gained significant interest in the field of endodontics [12]. Considerable research towards successful regeneration of pulp-dentine complex (PDC) is progressing which emphasises on replacement of damaged structures such as dentine, PDC cells and root structures [13]. Tissue regeneration and engineering is the most thought-provoking part of a tissue repair/regeneration programme because of pulp functional importance [14]. The regenerated tissue should be vascularised, innervated and possess the ability to generate new odontoblasts which can produce new dentin matrices that later become mineralised. The concept of regeneration became popular when Banchs and Trope in 2004 treated immature necrotic and permanent teeth with new procedure and termed it 'revascularization' [2]. Pulp revascularization was an important step by the endodontic community on its path to exploring avenues of pulp and dentin regeneration [15].

Previously our team had conducted numerous studies which include in vitro studies [16–21], review [22–25], survey [26,27], clinical trial [28–30]. Now we are focussing on retrospective studies. The aim of this survey was to study the level of awareness, current state of knowledge and opinions towards management of immature necrotic permanent teeth amongst the dentists in Chennai.

II. MATERIALS AND METHODS

An online survey was done with the structured questionnaire based on knowledge, attitude, practice survey among the dental students about management of immature necrotic permanent teeth.

Ethical approval

Ethical permission and approval for the project was obtained from the Institutional Review Board of Saveetha Institute of Medical and Technical Sciences, Chennai, India on Date 25/04/2020.

Sampling and data collection

This cross sectional survey was conducted among 100 dental undergraduate students. A snowball sampling was followed. A structured questionnaire consisting of 12 questions was shared online and 100 responses were obtained. Data entry was made in the Excel sheet, SPSS software was used to analyze the data. The advantages of online surveys is that it was economical, easy to create, wide reach and disadvantage is repeated and incomplete answers

Statistical analysis

The descriptive statistics were used to determine the responses given by the participants. Statistical analysis, Chi square test was used to assess the association between the year of study and the responses. And the results are depicted in the form of a bar chart [Figure 1-11].

III. RESULTS

In the present study two thirds of the participants have come across necrotic immature permanent teeth[Figure 2] . About 51% of the participants agreed with the fact that regenerative endodontic procedures include stem cells, scaffolds and growth factors whereas 49% were not aware of this[Figure 3]. 35% of the participants were aware that functional pulp can be regenerated with REP [Figure 4]. 78% of the participants felt that the REP is the better treatment option than apexification [Figure 5].

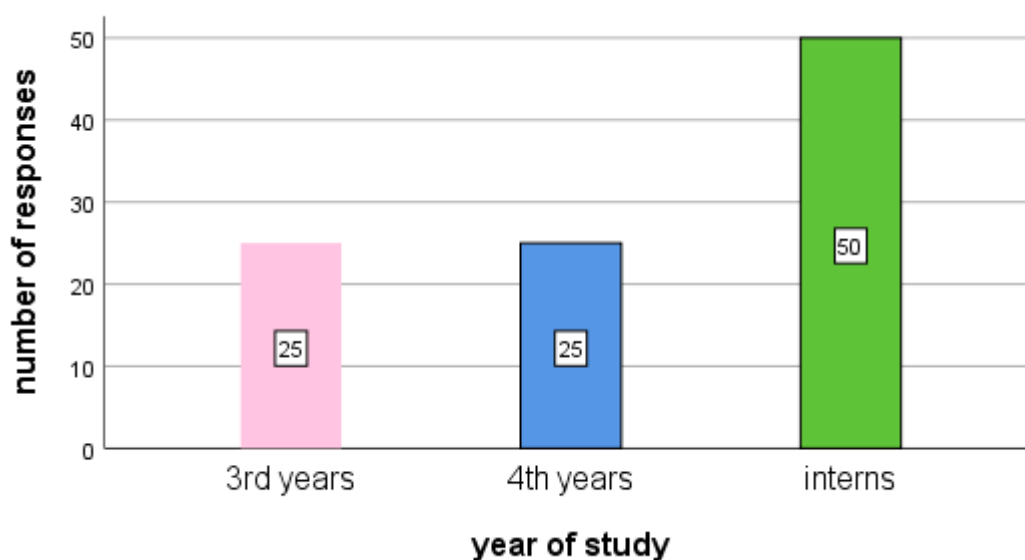


Figure1: Bar graph represents the number of respondents and year of study. X axis represents the year of study and Y axis represents number of respondents. Majority of the respondents were Interns (50%) followed by Final year (25%) and Third year(25%).

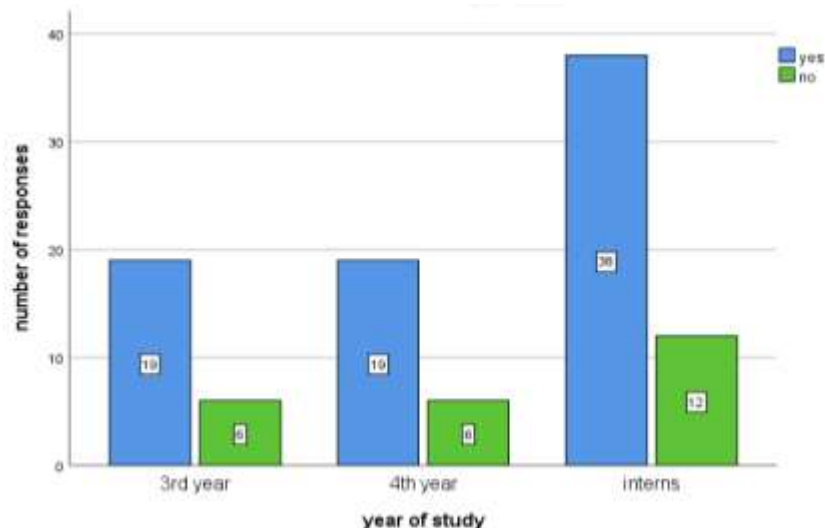


Figure 2: Bar graph represents the association between year of study and responses to the question “Have you come across an immature necrotic permanent tooth in your practice”. X axis represents the year of study and Y axis represents number of respondents. Majority of the respondents were ‘yes’. Chi square test shows no statistical difference in responses between years of study. [Pearson chi square p value = 0.415, (p>0.05)]. However, among the year of study, most of the interns responded ‘yes’.

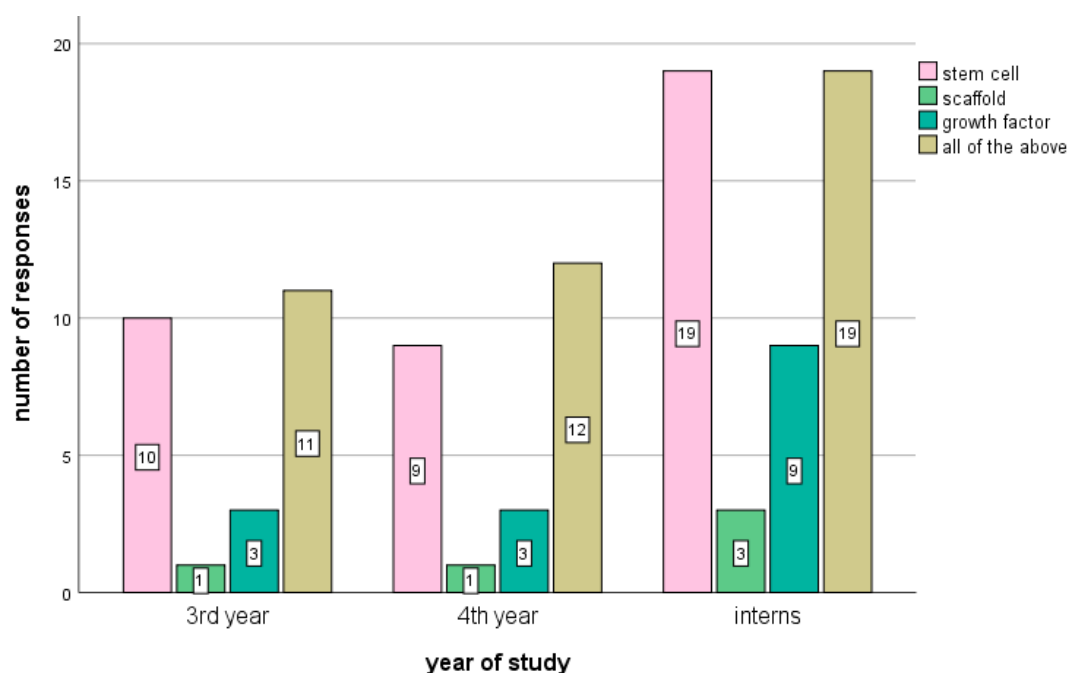


Figure 3: Bar graph represents the association between year of study and responses to the question “regenerative endodontic procedures include”. X axis represents the year of study and Y axis represents number of respondents. The majority of the respondents said all of the above. Chi square test shows no statistical difference in responses between years of study. [Pearson chi square p value = 0.973, (p>0.05)]. However, among the year of study, most of the interns responded ‘yes’.

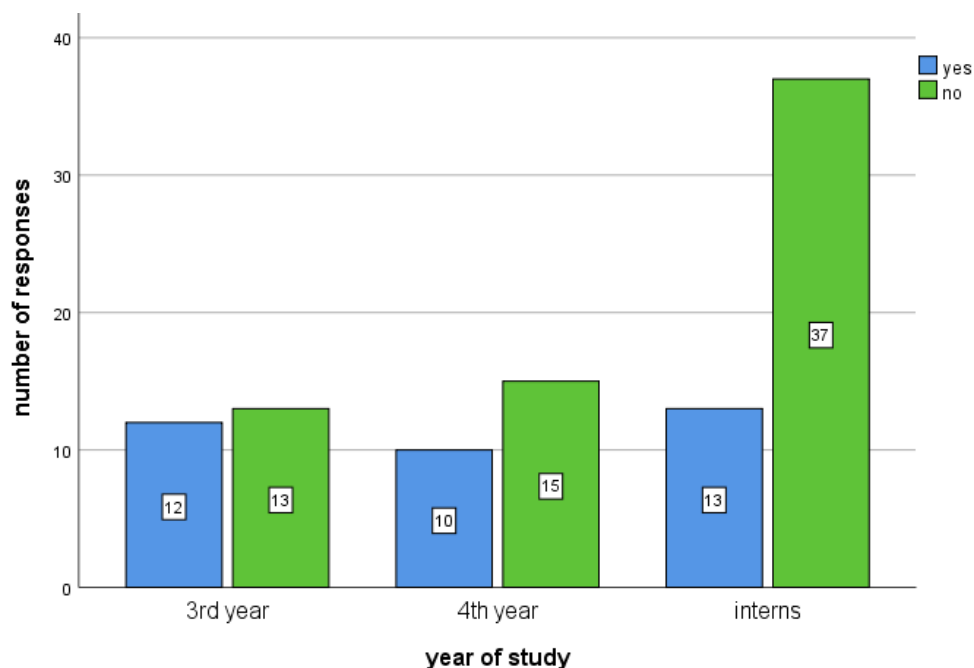


Figure 4: Bar graph represents the association between year of study and responses to the question “do you think functional pulp can be regenerated with REP”. X axis represents the year of study and Y axis represents number of respondents. The majority of the respondents were ‘yes’. Chi square test shows no statistical difference in responses between years of study. [Pearson chi square p value = 0.141, ($p > 0.05$)]. Students were unaware that pulp can be regenerated with REP.

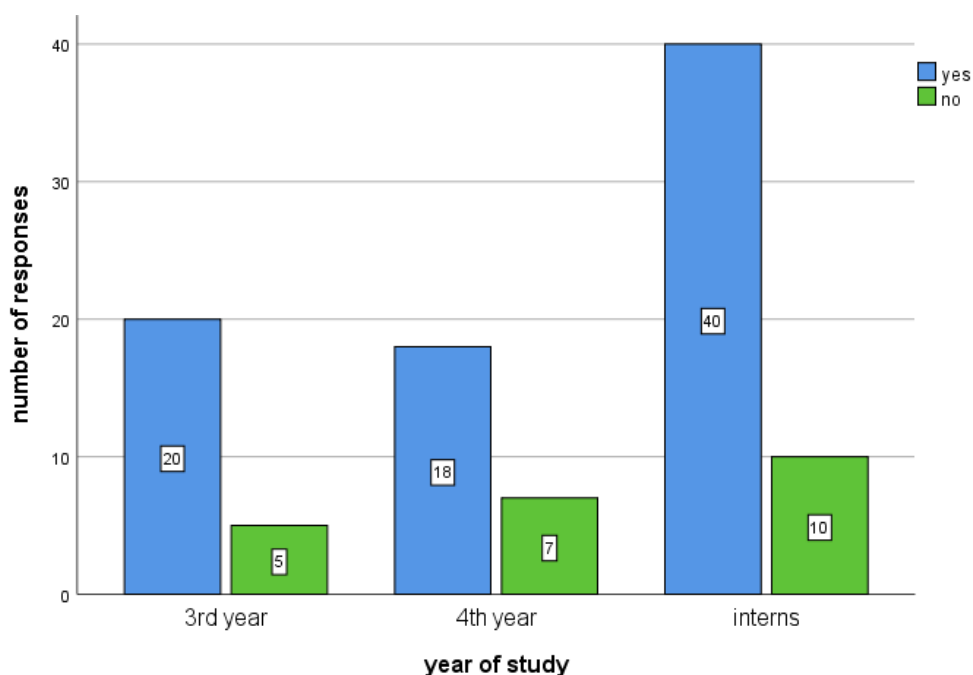


Figure 5: Bar graph represents the association between year of study and responses to the question “do you think REP is a better treatment option than apexification”. X axis represents the year of study and Y axis represents number of respondents. The majority of the respondents preferred REP is a better treatment option than apexification Chi square test shows no statistical difference in responses between years of study. [Pearson

chi square p value = 0.705, ($p > 0.05$)]. However, among the year of study, interns strongly agree with REP is better option.

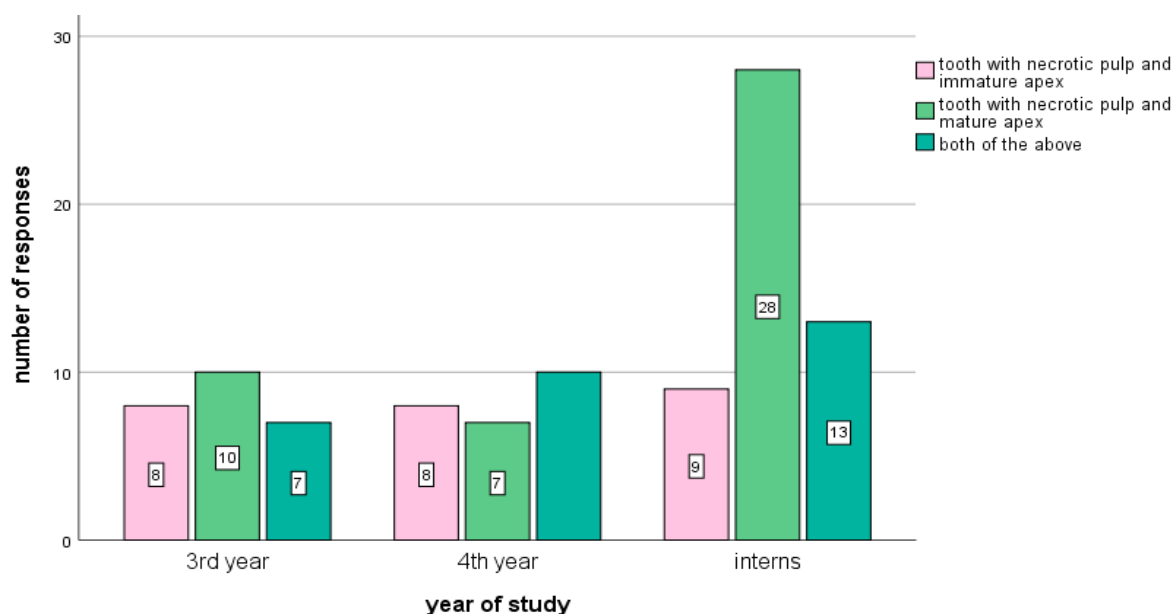


Figure 6: Bar graph represents the association between year of study and responses to the question “In which cases would you prefer doing REP”. X axis represents the year of study and Y axis represents number of respondents. The majority of the respondents said they prefer REP in tooth with necrotic pulp and mature apex. Chi square test shows no statistical difference in responses between years of study. [Pearson chi square p value = 0.186, ($p > 0.05$)]. Students were unaware that REP can be done in closed and open apex.

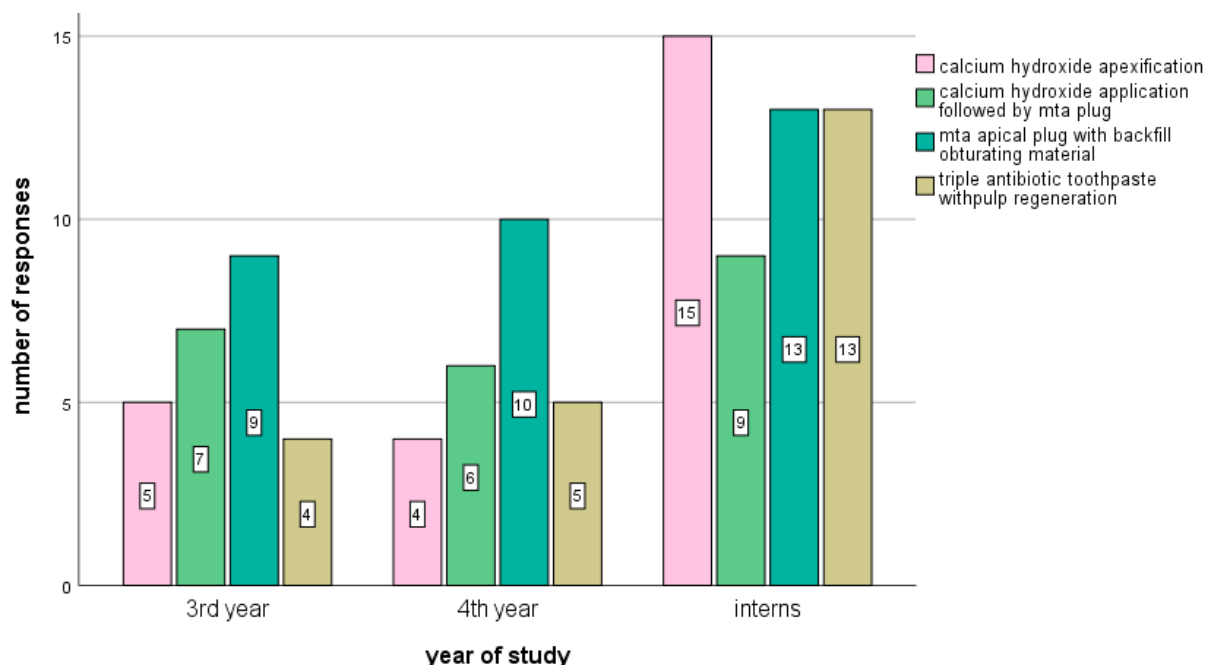


Figure 7: Bar graph represents the association between year of study and responses to the question “Which of the following treatments serve as a better mode of treatment for non-vital immature teeth”. X axis represents the year of study and Y axis represents number of respondents. The majority of the respondents preferred MTA plug with backfill obturating material non-vital immature teeth. Chi square test shows no statistical difference in responses between years of study. [Pearson chi square p value = 0.622, ($p > 0.05$)].

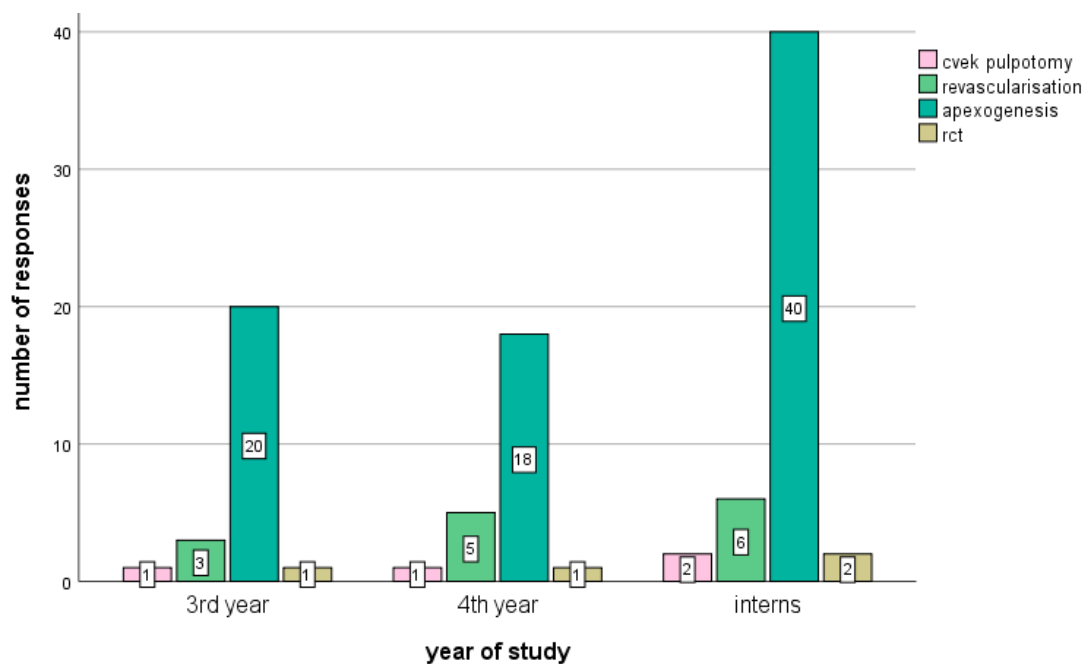


Figure 8: Bar graph represents the association between year of study and responses to the question “What is the treatment of NIPT when disease is limited to superficial coronal pulp”. X axis represents the year of study and Y axis represents number of respondents. Chi square test shows no statistical difference in responses between years of study. [Pearson chi square p value = 0.985, ($p > 0.05$)]. However, among the year of study, interns strongly agree with cveks pulpotomy.

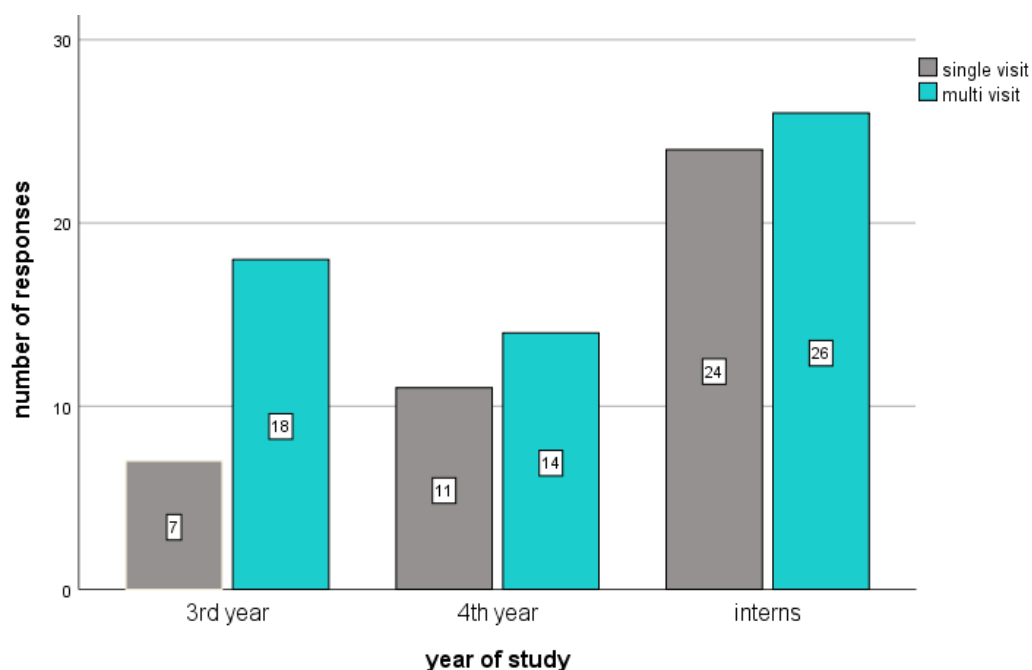


Figure 9: Bar graph represents the association between year of study and responses to the question “how many visits do you require to perform REP?”. X axis represents the year of study and Y axis represents number of respondents. Chi square test shows no statistical difference in responses between years of study. [Pearson chi square p value = 0.848, ($p > 0.05$)]. The respondents were unaware that REP is a multivisit procedure. However, among the year of study, most third years were aware.

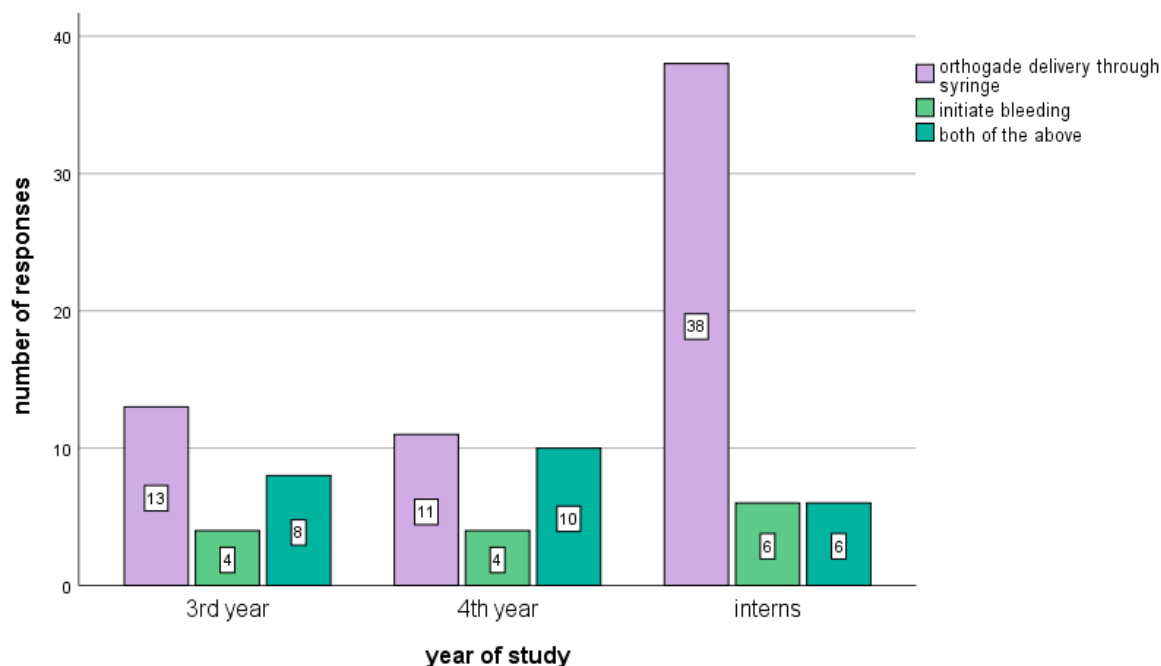


Figure 10: Bar graph represents the association between year of study and responses to the question “ how do you deliver stem cells into the root canal system”. X axis represents the year of study and Y axis represents number of respondents Chi square test shows no statistical difference in responses between years of study. [Pearson chi square p value = 0.121, (p>0.05)]. The majority of the interns preferred they would do it by using orthograde delivery through a syringe.

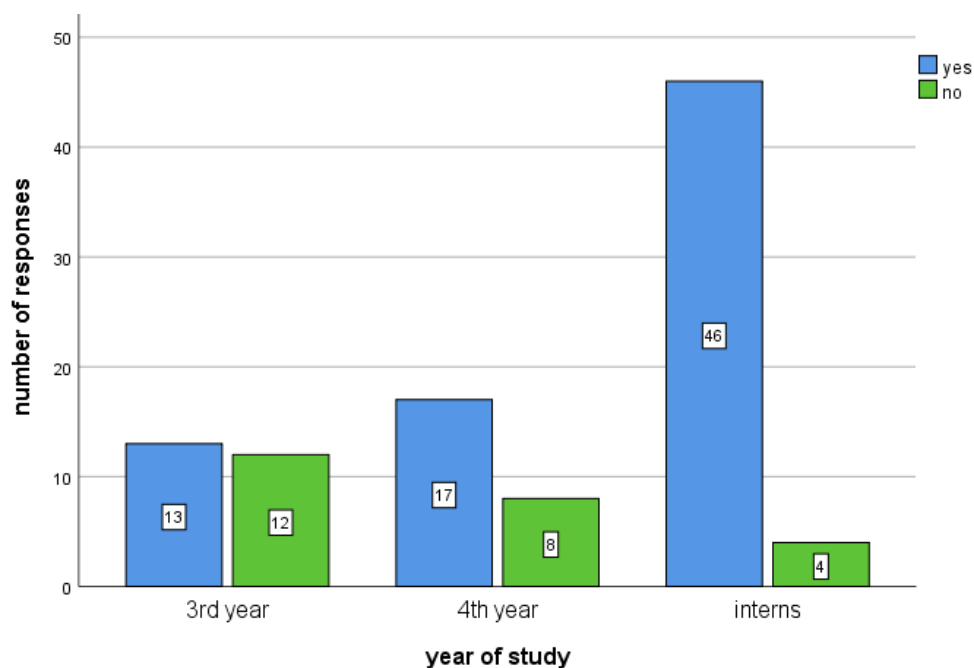


Figure 11: Bar graph represents the association between year of study and responses to the question “have you attended a course on regenerative endodontic procedures”. X axis represents the year of study and Y axis represents number of respondents. The majority of the respondents attended courses on dental stem cells. Chi square test shows no statistical difference in responses between years of study. [Pearson chi square p value = 0.265, (p>0.05)]. However, the majority of interns attended the course.

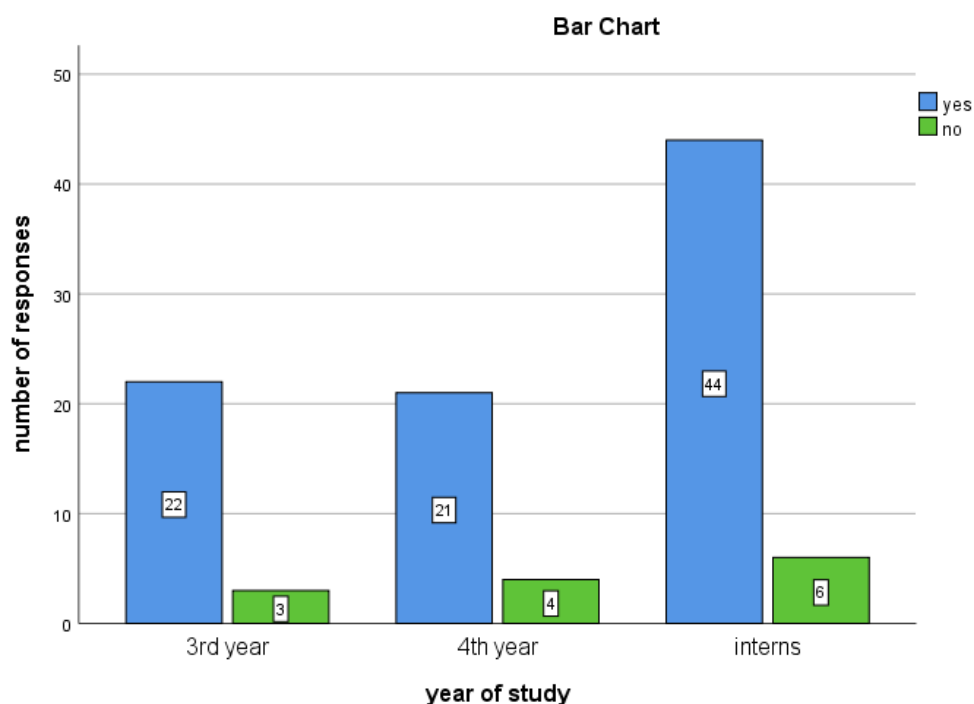


Figure 12: Bar graph represents the association between year of study and responses to the question “Are you willing to participate in training courses to learn more about regenerative dental treatment”. X axis represents the year of study and Y axis represents number of respondents. Chi square test shows no statistical difference in responses between years of study. [Pearson chi square p value = 0.876, ($p > 0.05$)]. The majority of the students want to learn about REP procedures by attending course

Here, 45% of the participants preferred REP for teeth with necrotic pulp and mature apex [Figure 6]. About 32% of the participants said they prefer MTA apical plug with backfill obturating technique as a better mode of treatment for treating non vital immature teeth followed by calcium hydroxide apexification [Figure 7]. More than two thirds of the participants 78% preferred apexogenesis as treatment of choice for necrotic immature teeth if it has open apex and disease limited to superficial coronal pulp [Figure 8].

Regarding the total number of visits to perform REP majority of the participants 58% said it is a multi visit procedure [Figure 9]. Majority of the participants, 62% preferred orthograde delivery through a syringe to deliver stem cells into the root canal system [Figure 10]. 76% of the total participants said they attended a course on stem cells [Figure 11]. And 87% of the participants are willing to attend a training course to learn more about the regenerative endodontic procedures [Figure 12].

IV. DISCUSSION

The survey yielded a positive response regarding management of immature necrotic permanent teeth among the participants who were dental students. Just over half of the participants (86%) have attended a CDE on stem cells and regeneration, which is very encouraging and reflects the increasing interest in this rapidly advancing field. Our results indicate that more than two-thirds of the participants (78%) believed that REPs are a better treatment option than apexification. This preference could be attributed to recent studies on REPs, which claim that REPs provide a better outcome than apexification in terms of increased root thickness and root length [31].

Moreover, a study on survival outcome of immature treated teeth has documented a higher (100%) survival rate for teeth treated with REPs, compared to 95% and 77.2% for MTA and Ca (OH)₂ apexification, respectively [32]. Various published studies have used different experimental models to regenerate dentin, pulp, and periodontal ligament-like tissues [12]. In 2004, Ohazama et al succeeded in developing rootless tooth-like

structures in rodents.[33] Young et al. succeeded in forming dentin and enamel-like structures by reimplanting bioengineered tooth and bone implants in adult rats[34].

In this study, more than two-thirds of the participants were more comfortable doing REPs on necrotic immature teeth. This finding is in accordance with most published literature, where most REP cases with successful outcomes were performed on necrotic immature teeth[35]. Furthermore, current evidence and research data on REPs on mature teeth show the healing of periapical lesions; however, they do not recover tooth vitality[36]. Therefore, in mature teeth, REPs don't necessarily provide any significant advantage over current conventional endodontic treatment modalities which have a high success rate (86%–98%)[37].

Around 40% of participants were using triple antibiotics paste (TAP) for disinfection, whereas 20% preferred to use Ca(OH)₂, and 39% used both. These results complement the findings of a review by Diogenes et al. on published cases and studies on REPs, where 51% were disinfected by TAP and 37% used Ca(OH)₂ for disinfection. The successful use of TAP in REPs and its antibacterial effect against the mixed population of microbes in the canal have been proven by different studies[38]. Several studies have supported the use of Ca(OH)₂ in REPs for its effective antibacterial properties and positive effect on the survival and proliferation of stem cells of the apical papilla (SCAP)[39]. The use of both Ca(OH)₂ and TAP for disinfection is recommended in the AAE's clinical considerations[19].

For the delivery of stem cells, around 55.1% of participants evoked bleeding from the periapical area, which is the most established and used method[39]. This survey shows a wide variation in the clinical protocol used to perform REPs. This finding is similar to Diogenes et al.'s findings in a review of 34 publications (2001–2013) on REPs, which revealed lack of a standardized treatment protocol such as the number of visits and disinfection routine[32]. Bukhari et al. and Almutairi et al. have also emphasized this aspect.[40]. Such variation in protocols can pose a challenge determining the factors that affect the clinical success of REPs and also affect the possibility of conducting a well-designed meta-analysis, as reported by Almutairi et al[41].

In clinical practices, almost half of the residents were doing some type of REP's, with a majority of these limited to use of membranes, scaffolds or bioactive materials. Most of the residents were conscious of other REP procedures but were unsure about its results. Half of them were of the opinion that REP's could be used in various applications like healing of periradicular bone, continued root development in immature teeth, pulp tissue revitalization within a root canal and tooth reimplantation. However, just one eighth respondents have found regenerative techniques valuable in treating necrotic immature teeth which constituted 20% of patients reporting to them. More than half the participants still consider the appliance of calcium hydroxide followed by MTA apical plug and backfilling with obturation material to be the optimum treatment for necrotic immature teeth. This gives an insight to the very fact that the residents aren't trained in performing advanced regenerative endodontic techniques. There is a requirement for continuing education and training programs associated with all treatments that accomplish pulp-dentin regeneration from the only blood clot revascularization method to the most complex treatment, which involves creating tissue-engineered dental pulp constructs within the laboratory and implanting them into cleaned and shaped root canals[42].

Safeguards need to be in place to guard research participants receiving somatic cell transplants, and patients at large from receiving unproven stem cell therapies. In India, Indian Council of Medical Research has taken an initiative to get down the rules concerning stem cell research which were revised in March 2012 [43]. These apply to all stakeholders' viz. individual researchers, organizations, sponsors, oversight committees and others, related to research on human stem cells and for his or her derivatives, both basic and clinical. However, there is a need for the creation of more expansive guidelines covering all REP's in addition to these guidelines to protect patients and health care providers.

V. CONCLUSION

The data from this survey revealed that dental undergraduate students of all the years had limited knowledge towards management of immature necrotic permanent teeth. Moreover, there is a need to conduct more seminars, CDE and workshop programmes to improve knowledge and clinical strategies regarding management of necrotic immature permanent teeth.

ACKNOWLEDGEMENT:

We, the authors of the manuscript, would like to thank and acknowledge Saveetha Dental College for providing us access to use the data for our study.

AUTHOR CONTRIBUTIONS:

All authors have equal contribution in bringing out this research work.

CONFLICT OF INTEREST:

This research project is self funded and it is not sponsored or aided by any third party. There is no conflict of interest.

REFERENCES

1. Chueh L-H, Ho Y-C, Kuo T-C, Lai W-H, Chen Y-HM, Chiang C-P. Regenerative Endodontic Treatment for Necrotic Immature Permanent Teeth. *J Endod.* 2009 Feb 1;35(2):160–4.
2. Banchs F, Trope M. Revascularization of Immature Permanent Teeth With Apical Periodontitis: New Treatment Protocol? *J Endod.* 2004 Apr 1;30(4):196–200.
3. Petrino JA, Boda KK, Shambarger S, Bowles WR, McClanahan SB. Challenges in Regenerative Endodontics: A Case Series. *J Endod.* 2010 Mar 1;36(3):536–41.
4. Al Qahtani SS, Aziz S, Al Garni H, Alaenazi MS, Others. What opinions do Saudi endodontic residents hold about regenerative endodontics? *Saudi Endodontic Journal.* 2019;9(1):1.
5. Al Ansary MAD, Day PF, Duggal MS, Brunton PA. Interventions for treating traumatized necrotic immature permanent anterior teeth: inducing a calcific barrier & root strengthening. *Dent Traumatol.* 2009 Aug;25(4):367–79.
6. Doyon GE, Dumsha T, von Fraunhofer JA. Fracture Resistance of Human Root Dentin Exposed to Intracanal Calcium Hydroxide. *J Endod.* 2005 Dec 1;31(12):895–7.
7. Nosrat A, Seifi A, Asgary S. Regenerative Endodontic Treatment (Revascularization) for Necrotic Immature Permanent Molars: A Review and Report of Two Cases with a New Biomaterial. *J Endod.* 2011 Apr 1;37(4):562–7.
8. Kahler SL, Shetty S, Andreasen FM, Kahler B. The Effect of Long-term Dressing with Calcium Hydroxide on the Fracture Susceptibility of Teeth. *J Endod.* 2018 Mar 1;44(3):464–9.
9. Cehreli ZC, Isbitiren B, Sara S, Erbas G. Regenerative Endodontic Treatment (Revascularization) of Immature Necrotic Molars Medicated with Calcium Hydroxide: A Case Series. *J Endod.* 2011 Sep 1;37(9):1327–30.
10. Mente J, Hage N, Pfefferle T, Koch MJ, Dreyhaupt J, Staehle HJ, et al. Mineral Trioxide Aggregate Apical Plugs in Teeth with Open Apical Foramina: A Retrospective Analysis of Treatment Outcome. *J Endod.* 2009 Oct 1;35(10):1354–8.
11. Yang M. Regenerative endodontics: a new treatment modality for pulp regeneration. *JSM Dent.* 2013;1(2):10–1.
12. Cordeiro MM, Dong Z, Kaneko T, Zhang Z, Miyazawa M, Shi S, et al. Dental Pulp Tissue Engineering with Stem Cells from Exfoliated Deciduous Teeth. *J Endod.* 2008 Aug 1;34(8):962–9.
13. Kim SG, Zhou J, Solomon C, Zheng Y, Suzuki T, Chen M, et al. Effects of Growth Factors on Dental

- Stem/Progenitor Cells. *Dent Clin North Am.* 2012 Jul 1;56(3):563–75.
14. Goodis HE, Kinaia BM, Kinaia AM, Chogle SMA. Regenerative Endodontics and Tissue Engineering: What the Future Holds? *Dent Clin North Am.* 2012 Jul 1;56(3):677–89.
 15. Torabinejad M, Turman M. Revitalization of Tooth with Necrotic Pulp and Open Apex by Using Platelet-rich Plasma: A Case Report. *J Endod.* 2011 Feb 1;37(2):265–8.
 16. Ramanathan S, Solete P. Cone-beam Computed Tomography Evaluation of Root Canal Preparation using Various Rotary Instruments: An in vitro Study. *J Contemp Dent Pract.* 2015;16(11):869–72.
 17. Siddique R, Sureshababu NM, Somasundaram J, Jacob B, Selvam D. Qualitative and quantitative analysis of precipitate formation following interaction of chlorhexidine with sodium hypochlorite, neem, and tulsi. *J Conserv Dent.* 2019;22(1):40.
 18. Rajendran R, Kunjusankaran RN, Sandhya R, Anilkumar A, Santhosh R, Patil SR. Comparative Evaluation of Remineralizing Potential of a Paste Containing Bioactive Glass and a Topical Cream Containing Casein Phosphopeptide-Amorphous Calcium Phosphate: An in Vitro Study. *Pesqui Bras Odontopediatria Clin Integr [Internet].* 2019;19. Available from: http://www.scielo.br/scielo.php?pid=S1983-46322019000100364&script=sci_arttext
 19. Noor S, Others. Chlorhexidine: Its properties and effects. *Research Journal of Pharmacy and Technology.* 2016;9(10):1755–60.
 20. Teja KV, Ramesh S, Priya V. Regulation of matrix metalloproteinase-3 gene expression in inflammation: A molecular study. *J Conserv Dent.* 2018;21(6):592.
 21. Mahalakshmi Nandakumar IN. Comparative evaluation of grape seed and cranberry extracts in preventing enamel erosion: An optical emission spectrometric analysis. *J Conserv Dent.* 2018;21(5):516.
 22. Rajakeerthi R, Ms N. Natural Product as the Storage medium for an avulsed tooth--A Systematic Review. *Cumhuriyet Dental Journal.* 2019;22(2):249–56.
 23. Kumar D, Antony S. Calcified Canal and Negotiation-A Review. *Research Journal of Pharmacy and Technology.* 2018;11(8):3727–30.
 24. Teja KV, Ramesh S. Shape optimal and clean more. *Saudi Endodontic Journal.* 2019 Sep 1;9(3):235.
 25. Ravinthar K, Others. Recent Advancements in Laminates and Veneers in Dentistry. *Research Journal of Pharmacy and Technology.* 2018;11(2):785–7.
 26. Jose J, Subbaiyan H. Different Treatment Modalities followed by Dental Practitioners for Ellis Class 2 Fracture--A Questionnaire-based Survey. *Open Dent J [Internet].* 2020; Available from: <https://opendentistryjournal.com/VOLUME/14/PAGE/59/FULLTEXT/>
 27. Manohar MP, Sharma S. A survey of the knowledge, attitude, and awareness about the principal choice of intracanal medicaments among the general dental practitioners and nonendodontic specialists. *Indian J Dent Res.* 2018 Nov 1;29(6):716.
 28. Ramamoorthi S, Nivedhitha MS, Divyanand MJ. Comparative evaluation of postoperative pain after using endodontic needle and EndoActivator during root canal irrigation: a randomised controlled trial. *Aust Endod J.* 2015;41(2):78–87.
 29. Hussainy SN, Nasim I, Thomas T, Ranjan M. Clinical performance of resin-modified glass ionomer cement, flowable composite, and polyacid-modified resin composite in noncarious cervical lesions: One-year follow-up. *J Conserv Dent.* 2018;21(5):510.
 30. Janani K, Palanivelu A, Sandhya R. Diagnostic accuracy of dental pulse oximeter with customized sensor holder, thermal test and electric pulp test for the evaluation of pulp vitality: an in vivo study. *Brazilian*

Dental Science. 2020;23(1):8.

31. Bose R, Nummikoski P, Hargreaves K. A Retrospective Evaluation of Radiographic Outcomes in Immature Teeth With Necrotic Root Canal Systems Treated With Regenerative Endodontic Procedures. *J Endod.* 2009 Oct 1;35(10):1343–9.
32. Jeeruphan T, Jantarat J, Yanpiset K, Suwannapan L, Khewsawai P, Hargreaves KM. Mahidol Study 1: Comparison of Radiographic and Survival Outcomes of Immature Teeth Treated with Either Regenerative Endodontic or Apexification Methods: A Retrospective Study. *J Endod.* 2012 Oct 1;38(10):1330–6.
33. Ohazama A, Modino SAC, Miletich I, Sharpe PT. Stem-cell-based Tissue Engineering of Murine Teeth. *J Dent Res.* 2004 Jul 1;83(7):518–22.
34. Young CS, Abukawa H, Asrican R, Ravens M, Troulis MJ, Kaban LB, et al. Tissue-Engineered Hybrid Tooth and Bone. *Tissue Eng.* 2005 Sep 1;11(9-10):1599–610.
35. Iwaya S-I, Ikawa M, Kubota M. Revascularization of an immature permanent tooth with apical periodontitis and sinus tract. *Dent Traumatol.* 2001 Aug;17(4):185–7.
36. Friedman S, Mor C. The success of endodontic therapy healing and functionality. *CDA J.* 2004;32(6):493–503.
37. Saoud TMA, Zaazou A, Nabil A, Moussa S, Lin LM, Gibbs JL. Clinical and Radiographic Outcomes of Traumatized Immature Permanent Necrotic Teeth after Revascularization/Revitalization Therapy. *J Endod.* 2014 Dec 1;40(12):1946–52.
38. Sharma S, Mittal N. A comparative evaluation of natural and artificial scaffolds in regenerative endodontics: A clinical study. *Saudi Endodontic Journal.* 2016 Jan 1;6(1):9.
39. Manguno C, Murray PE, Howard C, Madras J, Mangan S, Namerow KN. A survey of dental residents' expectations for regenerative endodontics. *J Endod.* 2012;38(2):137–43.
40. Bukhari S, Kohli MR, Setzer F, Karabucak B. Outcome of Revascularization Procedure: A Retrospective Case Series. *J Endod.* 2016 Dec 1;42(12):1752–9.
41. Almutairi W, Yassen GH, Aminoshariae A, Williams KA, Mickel A. Regenerative Endodontics: A Systematic Analysis of the Failed Cases. *J Endod.* 2019 May 1;45(5):567–77.
42. Utneja S, Nawal RR, Ansari MI, Talwar S, Verma M. A survey of attitude and opinions of endodontic residents towards regenerative endodontics. *J Conserv Dent.* 2013 Jul;16(4):314–8.
43. Farhat Yaasmeen Sadique Basha, Rajeshkumar S, Lakshmi T, Anti-inflammatory activity of *Myristica fragrans* extract. *Int. J. Res. Pharm. Sci.*, 2019 ;10(4), 3118-3120 DOI: <https://doi.org/10.26452/ijrps.v10i4.1607>
44. Ng Y-L, Mann V, Rahbaran S, Lewsey J, Gulabivala K. Outcome of primary root canal treatment: systematic review of the literature--Part 2. Influence of clinical factors. *Int Endod J.* 2008;41(1):6–31.