

Effectiveness of Honey Dressing on Healing of Diabetic Foot Ulcer: Systematic Review

Farida Farida^{1*}, Angga Miftakhul Nizar^{1,2}, Wa Ode Nurlina¹, Restiyana Agus¹

Abstract--- Honey is a natural product made by bees by using nectar from flowers. Honey dressing has been widely used for wound dressing, but there are still few studies that review the effectiveness of honey dressing in wound healing in patients. The objective of this study was to evaluate the effectiveness of honey dressing on the healing of wounds based on a literature study. The study was undertaken through a systematic review with the preferred reporting items for systematic reviews and meta-analyses (PRISMA). The literature search was through the Scopus, ProQuest, springer link, EBSCO and Sage databases in the last 10 years (2010-2020) using the keywords: wound care or wound treatment or wound management and honey dressing. There were 15 articles selected from 892 journal articles found. From all the journals analysed there were several comparisons used as a comparison of honey dressing for wound healing in reducing wound surface area, pain level, treatment costs, and increasing patient comfort level. Further research is needed to evaluate honey dressing so that it can be applied more widely as an alternative dressing for diabetic foot ulcers.

Keywords--- Wound Management; Honey Dressing; Modern Wound Care

I. INTRODUCTION

In patients with diabetes, if blood sugar levels are not controlled continuously there is a big risk of diabetic foot ulcers. This condition can cause severe and chronic complications that disrupt the patient's quality of life [1]. These complications include infection and amputation in the lower extremities and these have become one of the leading causes of disability and death among diabetic patients [2]. With a prevalence rate of 4-10%, DFU is not only a huge economic burden on patients, but can also affect their quality of life [1]. A diabetic foot ulcer is a wound that occurs in almost 15 percent of patients with diabetes and is commonly located on the bottom of the extremity. Of those who develop a foot ulcer, 6 percent will be hospitalized due to infection or other ulcer-related complications [2]. Various steps have been applied to overcome DFU including debridement, blood glucose control and infection prevention. Wound healing is the process of restoring the physical integrity of internal and external body structures that involves complex interactions between cells and several other factors [3]. The effectiveness of conventional methods that exist today is still lacking. Bandaging injuries plays an integral part in managing DFU [4],[6]. Different types of wound dressing can be applied to DFU, including a conventional dressing, functional dressing and honey dressing. Experts are increasingly aware of the value of choosing a suitable dressing to manage DFU, which can help speed up the process of wound healing, inhibit the process of spread of wounds and infections, and increase the rate of wound healing degeneration [5].

¹ STIKes Hutama Abdi Husada Tulungagung, Indonesia

² Faculty of Nursing Universitas Airlangga, Surabaya Indonesia

Corresponding author
Farida Farida
Email: poprimf@gmail.com

Several studies have reported that dressing using honey is more effective in managing DFU for now. Honey dressing is clinically defined as honey placed on a general surgical gauze, which is then applied to improve wound healing. Besides this, honey has been processed in such a way as to be able to act as an alternative in wound dressing [6]. Honey also needs to be processed to meet physiochemical standards to be used as an alternative in the treatment of DFU wounds. Several studies have shown that honey has broad-spectrum bactericidal properties, helps in the management of wound infections, increases epithelial proliferation and absorbs edema around the wound [7]. A prospective observational study randomly investigated 30 diabetic patients treated with honey bandages, and found that after three months of treatment, complete and significant healing was achieved in 43.3% of foot ulcers treated with honey pads, while there was a reduction in the area of the injured wound. Significant with the presence of healthy new tissue granulation in 43.3% of other patients [8].

This kind of research is very important, but the number of studies and data quality are limited. Jull et al. conducted a systematic review of the application of wound dressing using honey for all wounds, but this study did not provide subgroup analysis and special reports on DFU [9]. In addition, the previous systematic review, related to the effect of honey dressing on DFU, did not have quantitative synthesis [10]. Another specific meta-analysis for honey dressing applied to DFU had a very low number of subjects. It can be concluded that the use of honey pads in DFU has not been widely used [1]. Until now there is still less research that provides evidence that dressing the wound with honey is more effective than other dressings. Based on this, we conducted an analysis of published journals related to the use of honey wraps in the treatment of diabetic foot ulcer (DFU) wounds [8].

II. METHODS

- Search Method

This systematic review includes original journals which discuss the effects of wound care using honey on patients with diabetic foot ulcers in general, but there are also measurements of effectiveness in wound healing. A systematic literature search was carried out using several major databases such as Scopus, Proquest, Springer link, Ebsco and Sage by entering the keywords wound care or wound treatment or wound management and honey dressing and diabetic foot ulcer. There were no other restrictions that were used to maximize the literature search. The list of literature references was done manually. Search results on the Scopus database included 579 journals, Sage included 214 journals and Springer Link journals totaled 4 journals.

- Inclusion Criteria

Literary inclusion criteria included research using random clinical trial (RCT) methods, case studies or quasi experiments on the effectiveness of honey dressing on the extent of wound healing in patients with DFU with a limitation in terms of the years searched, namely 10 years (2007-2017). All journals used had to meet the PICO criteria and the samples used had to be humans not experimental animals [8]. Each sample had to include complaints of diabetes foot ulcer and a history of diabetes mellitus. The interventions used had to use honey and the comparison could be conventional or other modern dressings. All journals used had to be published in reputable journals in English. From a total of 797 research journals, there were 15 journals that met the researchers' inclusion criteria and were used as material for systematic review.

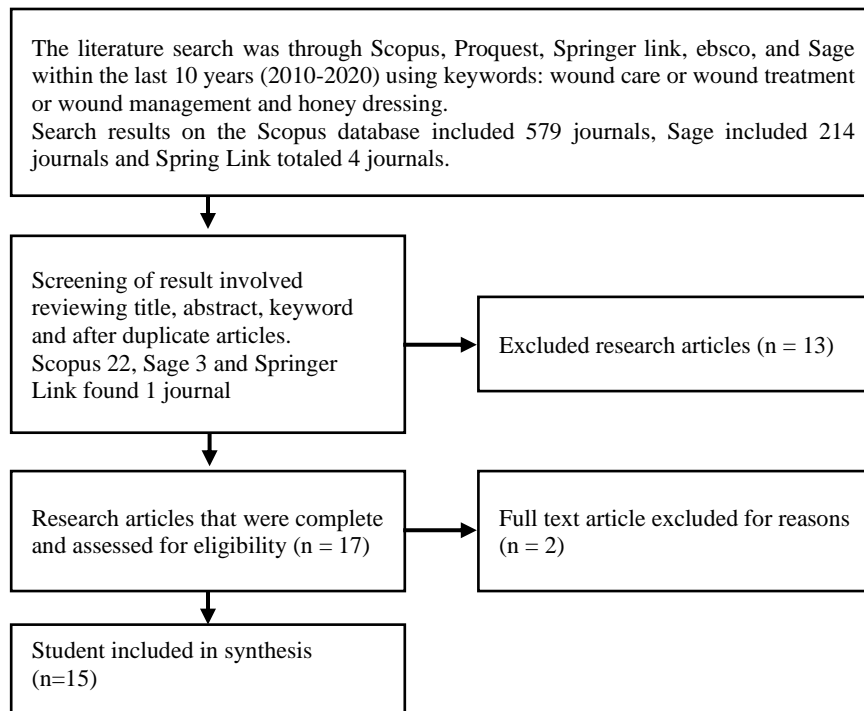


Figure 1 – Article selection process. Adapted from Alur PRISMA - *Preferred Reporting Items for Systematic Review and Meta Analysis*

III. RESULTS

- Characteristics of systematic review

The 15 journals that were analyzed consisted of various research designs including randomized controlled trials, quasi experiments, prospective randomized studies, and case studies. The majority of journals obtained were randomized controlled trials (RCT design), namely 8 journals. A total of 3 journals used a case study design and the rest used a quasi-experimental design. Participants used in journals varied with a maximum sample size of 150 respondents. Characteristics of wounds that were observed also varied from starting wounds in diabetic foot ulcer patients, chronic wounds, skin graft donors, infectious wounds and burns, but the majority of studies were on diabetic foot ulcers.

- Treatment of wounds using honey

From all the journals obtained and analyzed entirely using honey as an additional material in the dressing method [6]. Honey used varied from the use of bee honey [11], honey sialang, and manuka honey [6]. Honey preparations also varied in terms of how they were made at various stages so that some were gel and some were in the form of natural honey preparations [12].

The dose of honey in the dressing was not clearly stated as this depended on the extent of the wound and the need for honey in the dressing of the wound [11]. Replacing the dressing was done every 2-4 days depending on the severity of the wound [13]. Changing the dressing of course also adjusts the results of the study and analysis of nurses because it alters various aspects [6]. The replacement of dressings also depended on the type of wound; for example in wounds that produced a lot of pus, dressings were replaced more often; wounds that were in good condition, did not produce much pus and controlled blood sugar levels were dressed less frequently [14].

In essence, when using a modern dressing using a method of treatment with honey, wound care will be more effective and replacing the dressing will be less frequent so that tissue growth becomes more optimal [15]. Comparisons used in the

studies that have been analyzed were very varied, ranging from comparing the dressing of honey with povidone iodine, hydrocolloid, silver gel, and conventional wound care [16],[6].

- Measuring instruments for wound care effectiveness

Measurement of the effectiveness of wound care can be done using various instruments. Several studies were analyzed that used manual measurements of area, depth, and wound condition [17] [15]. There were also those who used standard instruments to measure wounds, and there were also several journals that used a combination of instruments to measure wound conditions such as using a visual analog scale to assess the quality of pain experienced by patients in the injured area; there were also those who used the Mueller-Hinton agar standard instrument (MHA) plate, or also used the Wound Healing Continuum (WHC), Thai Traditional Medicine Pressure Ulcer Assessment Tool (TTM-PUAT), Wound Assessment Tool (PWAT), Total Body Surface Area (TBSA), Pressure Ulcer Scale for Healing (PUSH), and the most commonly used instrument was the Bates-Jensen Wound Assessment Tool (BWAT) [6], [11], [18].

- Effectiveness of wound care using honey

The results of the analysis included 15 journals, all of them using honey preparations either in the form of gel or direct honey. There was one study that used a combination of honey with Thai herbal oil for the treatment of pressure ulcers [9], [11]. The results of the studies and the characteristics of the journals can be seen in Table 1 in the journal appendix.

IV. DISCUSSION

Based on all the journals that were analyzed, honey is very effective in healing wounds because it contains antibacterial and antioxidant properties and hydrogen peroxide which also helps kill harmful germs in the wound area and around the wound [19]. The use of honey can be modified with other additions such as Thai herbal oil or other ingredients that have also been tested such as hydrocolloids or silver gel. The antibacterial and hydrogen peroxide content in honey, in addition to killing bacteria, can increase the acceleration of granulation of tissue around the wound due to bacterial inhibition that is absent or minimal [10]. The challenge in dealing with bias in wound healing lies in the variety of wounds so that the only conclusion that can be drawn is that the use of honey is effective for use in wounds in general. In almost all journals, the number of participants studied was under one hundred and there were even those below 30 in terms of the number of samples [20].

Based on an analysis of 15 journals, the dosage formulations used for wound care used honey in liquid form most commonly and two journals used honey in the form of gel. The dosage used depended on the area of the wound and the type of wound and its characteristics. The decision of a doctor or nurse regarding how much honey was used as a dressing material depended on the initial analysis and assessment [21].

Honey is one alternative solution that can be used for non-pharmacological therapy. Honey can be used as a topical dressing on wounds in general or injuries to diabetic foot ulcers, burns, or infections due to trauma or post-surgery [6]. As a topical wound treatment, honey is a dressing that is easily absorbed by the skin, creating skin moisture and providing the necessary nutrients [6]. Honey is proven to have the ability to kill a number of bacteria including gram-positive and gram-negative bacteria. Honey causes an increase in osmotic pressure above the wound surface so that it can inhibit the growth of bacteria in the wound area [22].

Besides this, the antibacterial activity in honey occurs because of the content of hydrogen peroxide, flavonoids and hypertonic sugar concentrations [23]. Hydrogen peroxide is formed in honey by the activity of glucose oxidase energy which

produces gluconic acid and hydrogen peroxide from glucose. This enzyme is active when honey is diluted [6]. Hydrogen peroxide is an antiseptic because it acts as an antibacterial to inhibit about 60 types of aerobic bacteria or gram-negative or gram-positive anaerobes [10]. Flavonoids are antioxidants and antibiotics that function to strengthen and anticipate damage to blood vessels and active ingredients that function in an anti-inflammatory and anti-viral way [18]. The content of hypertonic sugar can have effects in inhibiting bacterial growth. In addition, honey also has a PH that ranges from 3.4 to 4.5.5 so that bacteria cannot maintain life on the PH [7].

Missing information about the extent and severity of the wound also needs to be taken into account. From all the journals, the inclusion criteria were more stringent in terms of, for example, the type of wound, the condition of the wound and the age of the patient because some of these things would affect wound healing. Wound care using honey also requires several evaluations such as dosage, honey preparation formulations and types of honey that can be used. Another challenge of this systematic review is the difficulty in finding similar literature about the characteristics and types of injuries, and the variations in the dosages used [13], [15].

V. CONCLUSION

This systematic review was compiled from 15 journals that were reviewed. Overall wound care using honey is more effective when compared to conventional wound care, wound care using povidone iodine or other similar materials. This effectiveness was assessed based on the length of wound care and the frequency of wound dressing replacement. Both of these will affect the costs incurred by the patient for wound care. Wound care using honey requires relatively less cost compared to other methods and is quite effective in preventing the spread of infections in wounds.

CONFLICT OF INTEREST

No conflicts of interest have been declared.

ACKNOWLEDGMENT

The authors of this study would like to thank the faculty of nursing and master of nursing study programme for providing the opportunity to present this study.

REFERENCES

- [1] M. Subrahmanyam, "Honey Dressing Accelerates Split-Thickness Skin Graft Donor Site Healing," *Indian J. Surg.*, vol. 77, no. December, pp. 261–263, 2015, doi: 10.1007/s12262-012-0789-9.
- [2] F. F. Abd El-Malek, A. S. Yousef, and S. A. El-Assar, "Hydrogel film loaded with new formula from manuka honey for treatment of chronic wound infections," *J. Glob. Antimicrob. Resist.*, vol. 11, pp. 171–176, 2017, doi: 10.1016/j.jgar.2017.08.007.
- [3] S. Jeffery, N. Henry, and I. Radotra, "Properties and use of a honey dressing and gel in wound management," *Br. J. Nurs.*, vol. 28, no. 6, pp. S30–S35, 2019, doi: 10.12968/bjon.2019.28.6.s30.
- [4] B. G. Visavadia, J. Honeysett, and M. H. Danford, "Manuka honey dressing: An effective treatment for chronic wound infections," *Br. J. Oral Maxillofac. Surg.*, vol. 46, no. 1, pp. 55–56, 2008, doi: 10.1016/j.bjoms.2006.09.013.
- [5] S. Chotchoungchatchai, O. Krairit, P. Tragulpiankit, and S. Prathanturug, "The efficacy of honey and a Thai Herbal Oil preparation in the treatment of pressure ulcers based on Thai traditional medicine wound diagnosis versus standard practice: An open-label randomized controlled trial," *Contemp. Clin. Trials Commun.*, vol. 17, 2020, doi: 10.1016/j.conctc.2020.100538.
- [6] S. S. Tin and V. Wiwanitkit, "Honey Dressing vs. Povidone Iodine Dressing," *Indian J. Surg.*, vol. 77, no. December, p. 1496, 2015, doi: 10.1007/s12262-014-1198-z.
- [7] R. Zeleníková and D. Vyhlídalová, "Applying honey dressings to non-healing wounds in elderly persons

- receiving home care,” *J. Tissue Viability*, vol. 28, no. 3, pp. 139–143, 2019, doi: 10.1016/j.jtv.2019.04.002.
- [8] S. Herianto Ritonga and N. Masraini Daulay, “Effectiveness of using sialang honey on wound bed preparation in diabetic foot ulcer,” *Enferm. Clin.*, vol. 29, no. xx, pp. 88–90, 2019, doi: 10.1016/j.enfcli.2018.11.028.
- [9] T. E. Udwardia, “Ghee and Honey Dressing for Infected Wounds,” *Indian J. Surg.*, vol. 73, no. 4, pp. 278–283, 2011, doi: 10.1007/s12262-011-0240-7.
- [10] M. Nasiri, S. Fayazi, S. Jahani, L. Yazdanpanah, and M. H. Haghighizadeh, “The effect of topical olive oil on the healing of foot ulcer in patients with type 2 diabetes: A double-blind randomized clinical trial study in Iran,” *J. Diabetes Metab. Disord.*, vol. 14, no. 1, pp. 1–10, 2015, doi: 10.1186/s40200-015-0167-9.
- [11] S. Gulati, A. Qureshi, A. Srivastava, K. Kataria, P. Kumar, and A. B. Ji, “A Prospective Randomized Study to Compare the Effectiveness of Honey Dressing vs. Povidone Iodine Dressing in Chronic Wound Healing,” *Indian J. Surg.*, vol. 76, no. 3, pp. 193–198, 2014, doi: 10.1007/s12262-012-0682-6.
- [12] K. R. Hixon *et al.*, “A Critical Review and Perspective of Honey in Tissue Engineering and Clinical Wound Healing,” *Adv. Wound Care*, vol. 8, no. 8, pp. 403–415, 2019, doi: 10.1089/wound.2018.0848.
- [13] C. Wang, M. Guo, N. Zhang, and G. Wang, “Effectiveness of honey dressing in the treatment of diabetic foot ulcers: A systematic review and meta-analysis,” *Complement. Ther. Clin. Pract.*, vol. 34, no. May, pp. 123–131, 2019, doi: 10.1016/j.ctcp.2018.09.004.
- [14] M. D. Hadagali and L. S. Chua, “The anti-inflammatory and wound healing properties of honey,” *Eur. Food Res. Technol.*, vol. 239, no. 6, pp. 1003–1014, 2014, doi: 10.1007/s00217-014-2297-6.
- [15] N. Yusof, A. H. Ainul Hafiza, R. M. Zohdi, and M. Z. A. Bakar, “Development of honey hydrogel dressing for enhanced wound healing,” *Radiat. Phys. Chem.*, vol. 76, no. 11–12, pp. 1767–1770, 2007, doi: 10.1016/j.radphyschem.2007.02.107.
- [16] B. Hashemi, A. Bayat, T. Kazemei, and N. Azarpira, “Comparison between topical honey and mafenide acetate in treatment of auricular burn,” *Am. J. Otolaryngol. - Head Neck Med. Surg.*, vol. 32, no. 1, pp. 28–31, 2011, doi: 10.1016/j.amjoto.2009.07.005.
- [17] H. Mohamed, B. El Lenjawi, M. A. Salma, and S. Abdi, “Honey based therapy for the management of a recalcitrant diabetic foot ulcer,” *J. Tissue Viability*, vol. 23, no. 1, pp. 29–33, 2014, doi: 10.1016/j.jtv.2013.06.001.
- [18] M. Subrahmanyam, “Honey dressing versus boiled potato peel in the treatment of burns: A prospective randomized study,” *Burns*, vol. 22, no. 6, pp. 491–493, 1996, doi: 10.1016/0305-4179(96)00007-1.
- [19] R. Fauziningtyas *et al.*, “The experiences of grandparents raising grandchildren in Indonesia,” *Work. with Older People*, vol. 23, no. 1, pp. 17–26, 2019, doi: 10.1108/WWOP-10-2018-0019.
- [20] S. P. Dubhashi and R. D. Sindwani, “A Comparative Study of Honey and Phenytoin Dressings for Chronic Wounds,” *Indian J. Surg.*, vol. 77, no. December, pp. 1209–1213, 2015, doi: 10.1007/s12262-015-1251-6.
- [21] P. Goharshenasan, S. Amini, A. Atria, H. Abtahi, and G. Khorasani, “Topical application of honey on surgical wounds: A randomized clinical trial,” *Forsch. Komplementarmed.*, vol. 23, no. 1, pp. 12–15, 2016, doi: 10.1159/000441994.
- [22] M. Nikpour, M. A. Shirvani, M. Azadbakht, R. Zanjani, and E. Mousavi, “The effect of honey gel on abdominal wound healing in cesarean section: A triple blind randomized clinical trial,” *Oman Med. J.*, vol. 29, no. 4, pp. 255–259, 2014, doi: 10.5001/omj.2014.68.
- [23] L. Labban, “Honey as a promising treatment for diabetic foot ulcers (DFU),” *JMS - J. Med. Soc.*, vol. 28, no. 2, pp. 64–68, 2014, doi: 10.4103/0972-4958.141064.

VII. APPENDIX

N o	Title and author	Population	Design Penelitian	Intervention	Measure	Analysis	Result
1	Compare the Effectiveness of Honey Dressing vs. Povidone Iodine Dressing in Chronic Wound Healing (Sonia, 2014)	Forty-five subjects were randomized into two groups i.e., honey & povidone iodine dressing group. Dressing was done on alternate day	A prospective randomized study	1. Intervention: Giving dressings using honey 2. Comparison: Giving dressings using	Visual analog scale (VAS) From these tracings wound surface area (in cm ²) was determined by com- puter image analysis with software	Friedman test and Wilcoxon rank sum (Mann–Whitney) with STATA software	There was a significant decrease in the wound surface area, pain score & increase in comfort score in honey

No	Title and author	Population	Design Penelitian	Intervention	Measure	Analysis	Result
		basis for 6 weeks of follow-up period. Wound healing status was assessed at 2 weekly intervals till 6 weeks.		povidone iodine	package IMAGE-Pro plus (version 4.1)	(version 9.1)	dressing group in comparison to the povidone iodine group at 0.05 level of significance. Honey dressing is highly effective in achieving healing in chronic wounds as compared to povidone iodine dressing.
2	Antibacterial properties of tualang honey and its effect in burn wound management (Nasir et al., 2010)	A total of 10 patients, ages 2 - 60 years old, with partial thickness burns (< 30%) and requiring tangential excision were included in this study after consent.	A comparative study	1. Independent: honey dressing adventure 2. Dependent: antibacterial effect	Mueller-Hinton - agar (MHA) plate		Tualang honey has a bactericidal as well as bacteriostatic effect. It is useful as a dressing, as it is easier to apply and is less sticky compared to manuka honey. However, for gram positive bacteria, tualang honey is not as effective as usual care products such as silver-based dressing or medical grade honey dressing. The study results showed that the application of honey dressings to non-healing wounds resulted in
3	Applying honey dressings to non-healing wounds in elderly persons receiving home care (Renáta, 2019)	The sample comprised 40 Czech home care clients (aged over 65 years) with non-healing wounds who were randomly assigned to two	A prospective interventional study	1. Intervention: honey dressing 2. Comparison: conventional dressing	Visual Analog Scale Wound assessment: location, size, wound bed condition, Wound Healing Continuum (WHC),	Chi-square test. B Fisher's exact test with Stata v. 13.	The study results showed that the application of honey dressings to non-healing wounds resulted in

No	Title and author	Population	Design Penelitian	Intervention	Measure	Analysis	Result
		groups. Wounds were treated with honey (intervention group) or conventional (controls) dressings.			amount and color of exudate, odor, description of the wound edges and adjacent area, pain, other complaints and Photographic Wound Assessment Tool (PWAT)		faster healing, wound size reduction and lower pain intensity.
4	The efficacy of honey and a Thai Herbal Oil preparation in the treatment of pressure ulcers based on Thai traditional medicine wound diagnosis versus standard practice (Somtanuek, 2020)	Sixty-six participants, with pressure ulcers at least stage II-IV or unstageable, were allocated to two groups via minimization. A TTM practice group received honey or THO depending on the TTM diagnosis via the Thai Traditional Medicine Pressure Ulcer Assessment Tool (TTM-PUAT).	An open-label randomized controlled trial	1. Intervention: honey or THO depending on the TTM 2. Comparison: advanced dressings	Thai Traditional Medicine Pressure Ulcer Assessment Tool (TTM-PUAT). Pressure Ulcer Scale for Healing (PUSH). Bates-Jensen Wound Assessment Tool (BWAT) mobile phone camera	The t-test and the Mann-Whitney test. Fisher's exact test or Yates' chi-square test were used for categorical data. Friedman's test and the Wilcoxon signed rank test.	Both TTM practice and standard practice showed a significant reduction in PUSH scores after treatments. TTM practice and standard practice accelerated pressure ulcer healing without statistically significant difference between the practices, during 6 weeks in a home-based care setting. This finding supported the TTM practice as an alternative treatment for pressure ulcer. Marked reduction in odor and discharge, greatly improving quality of life Reduction in pain in all cases, but poor overall results. Overall good results.
5	Ghee and Honey Dressing for Infected Wounds (Teheyton, 2011)	a) Eight cases of fungating malignant lesions. b) Thirteen chronic venous ulcers. c) Twenty-nine diabetic foot ulcers. d) Eleven patients with infected ventral hernia mesh hernioplasty. e) Eleven patients with post-	Descriptive	1. Intervention: honey and ghee dressing 2. Comparison: traditional dressing	Wound assessment: location, size, wound bed condition, Wound Healing Continuum (WHC), amount and color of exudate, odor, description of the wound edges and adjacent area, pain observed	-	

No	Title and author	Population	Design Penelitian	Intervention	Measure	Analysis	Result
		cesarean wound dehiscence.			for evidence of infection, excessive exudate or leakage.		Uniformly good results
6	Effectiveness of using sialang honey on wound bed preparation in diabetic foot ulcer (Sukhri, 2018)	The population in this study were all patients with diabetic foot ulcer in Padangsidimpua n City. The sampling technique used	Quasi experiment with one group pre-test post-test design	1. Intervention : the moisture balance method used dressings with sialang honey 2. Comparison : traditional dressing	This research used observation sheet wound bed score	Wilcoxon test with 95% confidence level.	After analyzing the data it could be concluded that sialang honey was effective in stimulating wound bed preparation in diabetic foot ulcer with a p value of 0.011.foot ulcer.
7	Honey Dressing versus boiled potato peel in the treatment of burns (Subrahmanyam , 2019)	In the 50 patients treated with honey, 90 per cent of wounds were rendered sterile within 7 days. In the 50 patients treated with boiled potato peel dressings, persistent infection was noted within 7 days.	A prospective randomized study	1. Intervention: honey dressing 2. Comparison: boiled potato peel	The burn surface area ranged (TBSA) observed for evidence of infection, excessive exudate or leakage.	Chi-square test.	In this prospective study, honey caused wounds to heal earlier by making the wounds sterile by its antibacterial effect. Potato peels, on the other hand, did not show any antibacterial activity as evidenced by the persistence of the organisms in culture swab study. The boiled potato peel dressings
8	Hydrogel film loaded with new formula from manuka honey for treatment of chronic wound infections (Malek, 2017)	Pathogenic isolates of Staphylococcus aureus, Streptococcus pyogenes, Acinetobacter baumannii, Pseudomonas aeruginosa icinfected wounds at Alexandria Main University Hospital	Quasi experiment	1. Intervention: hydrogel film is loaded with a new formula from manuka honey 2. Comparison: anti-bacterial effectiveness	The antibacterial activity of all honey types was determined by the Kirby–Bauer disk diffusion method.		Hydrogel loaded with a natural formula extracted from manuka honey is a ready-to-use wound dressing. It has antibacterial activity, accelerates wound healing and promotes exudate

No	Title and author	Population	Design Penelitian	Intervention	Measure	Analysis	Result
		(Alexandria, Egypt)					absorption, introducing a promising treatment for chronic wounds, bed sores and diabetic foot infections.
9	Manuka honey dressing: An effective treatment for chronic wound infections (Visavadia, 2008)	1. Case 1 An 80-year-old man had a split skin graft harvested from his upper arm in May 2005 (Fig. 1A). 2. Case 2 A 64-year-old man had a radial forearm flap donor site grafted with an abdominal full thickness skin graft.	Case study	1. Intervention: honey dressing 2. Comparison: effectiveness in infectious wounds	Observed for evidence of infection, excessive exudate or leakage.	Research has also indicated that honey may possess anti-inflammatory activity and stimulate immune responses. In vitro studies have shown increased release of tumor necrosis factor-alpha, interleukin-1beta and interleukin-6 with manuka honey, and have suggested that the effect of honey on wound healing may be in part related to the stimulation of inflammatory cytokines from monocytes. It has been claimed that honey dressings have been shown to be a reliable and cost-effective choice, particularly in developing countries (Moghazy et al., 2010). They also offer a viable alternative to silver-based dressings.	
10	Properties and use of a honey dressing and gel in wound management (Jeffery, 2019)	In cases 1, 3 and 4 just gauze was used and in case 2 gauze and gel were used together. The four cases listed cover a wide variety of wound types and patient demographics and comorbidities.	Case studies	1. Interventions: honey dressing and gel 2. Comparison: effective wound healing	The size of burn was estimated as be 1-2% of the total body surface area (TBSA)	It has been claimed that honey dressings have been shown to be a reliable and cost-effective choice, particularly in developing countries (Moghazy et al., 2010). They also offer a viable alternative to silver-based dressings.	

No	Title and author	Population	Design Penelitian	Intervention	Measure	Analysis	Result
11	The Effect of Honey Gel on Abdominal Wound Healing in Cesarean Section (Maryam, 2014)	Women with cesarean section were randomly designated as drug (37 cases) and placebo (38 cases) groups. The drug group received local honey gel 25%, while the placebo group received similar free-honey gel on abdominal cesarean incision twice a day for 14 days.	A triple blind randomized clinical trial	1. Intervention: honey gel 2. Comparison: effectiveness in post caesarean section wounds	REEDA scale (Redness, Edema, Discharge and Approximation of wound edges) was used to assess wound healing.	Chi-square, t-test and the repeated measurement test.	Honey was effective in healing the cesarean section incision. Using topical honey is suggested as a natural product with rare side effects in order to reduce the complications of cesarean wounds.
12	Honey based therapy for the management of a recalcitrant diabetic foot ulcer (Hashim, 2014)	The case is discussed in relation to various modalities targeting diabetic foot ulceration in the literature.	Case study	The patient was treated with strict offloading using a pair of crutches, debridement of necrotic tissue using a sharp scalpel and commercial honey applied daily and covered with a glycerin-based dressing	Wound assessment: location, size, wound bed condition, Wound Healing Continuum (WHC), amount and color of exudate, odor, description of the wound edges and adjacent area, pain	-	Currently, there is a paradigm shift in the fight against the diabetes plague and its multiple comorbidities including diabetic foot ulcers; therefore, primary care physicians must take a leading role in this battle in order to improve quality of life and save individuals from amputations.
13	Topical Application of Honey on Surgical Wounds: (Goharshenasan, 2015)	In 15 patients with mammoplasty and one patient with mastopexy, right and left incisions were divided into two equal parts, one part covered with honey dressing and the other part with conventional dressing.	A randomized clinical trial	1. Intervention : topical application of honey on surgical site 2. Comparison : the healing process	Visual Analog Scale	Wilcoxon signed- rank test	Wilcoxon signed- rank test showed significant difference between honey and conventional dressing outcomes at third and sixth month ($p < 0.001$). The healing process of the surgical wound and its final aesthetic

No	Title and author	Population	Design Penelitian	Intervention	Measure	Analysis	Result
14	Honey and Phenytoin Dressings for Chronic Wounds (Siddharth, 2015)	The study included 150 patients, 3 groups of 50 each (group A, honey dressing; group B, phenytoin dressing; group C, saline dressing).	A comparative study	1. Intervention : honey and phenytoin dressing 2. Comparison : effectiveness in healing chronic wounds	E assessing the time required for wound healing (appearance of granulation tissue, comparison of initial and final wound areas, percentage reduction of the wound after 3 weeks of treatment), eradication of infection (a negative culture report), visual analogue scale on days 5, 10, 15 and 20) and the hospital stay.	The results were analyzed using chi-square test.	result could be improved by using honey dressing. The appearance of granulation tissue was faster with significant wound area reduction after 3 weeks in groups A and B compared to group C. The outcomes of the use of honey and phenytoin as wound dressings are beneficial and comparable. Honey provides quicker pain relief and removes malodor more effectively.
15	Honey Dressing Accelerates Split-Thickness Skin Graft Donor Site Healing (M. Subrahmanyam, 2015)	One hundred chits were prepared, 50 for group 1 and 50 for group 2 at the beginning of the study, and the patients were allotted to either group (group 1, honey treated; group 2, Vaseline gauze treated) depending on which chit they picked up.	Randomized controlled trials	1. Intervention: honey dressing 2. Comparison: accelerates split-thickness skin graft donor site healing	The following observations were recorded in all patients: leakage of exudate from the dressing, skin reactions, pain, epithelialization, and cosmetic appearance.	Chi-square test.	The use of honey-impregnated gauze promotes healing; it is effective, comfortable for the patients, safe and results in excellent cosmetic outcome and makes an ideal dressing for skin graft donor sites.